

Checkup

Volume 46 • Issue 1 • Spring 2017



WEST COAST
DISTRICT DENTAL ASSOCIATION

A COMPONENT OF THE
AMERICAN & FLORIDA DENTAL ASSOCIATIONS

Good Times & Tan Lines

Mission: Helping Members Succeed

Culture: The Reliable Resource for Dentists

Values: Service, Commitment, Integrity and Excellence

Summer Meeting
Brochure Inside!

President's Message



Melissa M. Grimaudo, DMD

In my President's Message last year, I focused on how the dental association can help you. I wrote about the support you have from our team at all levels, from the ADA to the WCDDA. But now we need YOU to give back to our great profession. Our support staff can do a lot, but we need YOUR talents and expertise.

There are volunteer opportunities to fit your style, personality and schedule. You can be involved through leadership and planning, by providing treatment or helping to supervise the practice of dentistry. They are all unique positions that only YOU can fill.

Lots of important information is disseminated at your local dental meeting. Make sure you are there to hear what is going on. New leadership in the dental association is crucial to bring fresh ideas and continually grow. Your commitment can be as limited as helping to plan an event or longer-term as an officer on the association leadership line. Do not worry if you have not done it before, we welcome diversity in experience and background.

Providing dental care for those who cannot afford it is a way to give back that is just as rewarding. Whether it is a local clinic or in your office with *Donated Dental Services*, there are ways you can make a difference at your own comfort level. I am sure you have heard about the Florida Mission of Mercy (FLA MOM). The fourth FLA MOM is being planned here in our district on March 9-10, 2018, in Lee county. Mark your calendars and sign up early! It is an awesome experience to be part of a huge event that has a dramatic impact on the lives of thousands of people.

Dentists are needed to regulate our profession. The FDA is looking for dentists to apply for the Florida Board of Dentistry. As a Board member you would uphold the quality of dentistry in our state. Another way to promote standards is as a Dental Board Examiner. Florida-licensed dentists are needed to moderate and evaluate those applying to practice in our state.

We all benefit from our profession. Now is your chance to pay it forward. I encourage you to be involved. With your commitment we will make our association better.

Thank you for giving me the opportunity to serve YOU. 🍷

Melissa M. Grimaudo, DMD
WCDDA President

If you are interested in volunteering at local clinics or becoming more involved, visit www.floridadental.org/foundation/programs or complete the enclosed Connection Card. If you are interested in serving on the BOD as a Board Examiner, contact FDA Governmental Affairs office at (800) 326-0051.

INSIDE THIS ISSUE

2017 Annual Meeting and Events . . .	1
DDOH Perspective	3
Importance of Membership/Dates . . .	4
New Members and Memoriam	6
Summer Meeting Brochure & Registration Form	7/8
Association Business/ Important Information	9
Clinical Case Report	10-13
Classifieds	16
Tip of the Tongue	17

2017 Annual Meeting Highlights & Events

To view more meeting photos, visit <http://wccdaphotoalbums.shutterfly.com/>.



President, **Dr. Melissa Grimaudo** (c) pictured with Annual Meeting award recipient (l), **Dr. Terry Buckenheimer** who received the Distinguished Service Award, **Dr. Robin Nguyen** (r) who received the Daniel Bertoch Leadership Award.



Congratulations to **Dr. Madeline Berk** (pictured) for winning the Annual Meeting Raffle - \$300 Apple Gift Card and to **Dr. Elizabeth Perez Diaz** for winning The Ritz-Carlton & CE package during the Summer Meeting in Naples on August 4-6, 2017.



New Dentist Group
(L: R) **Dr. Brian Mannari, Dr. Jennifer Fiorica, Dr. Kristie Johnson, Dr. Jason Watts, Dr. Stephanie Mazariegos, Dr. Todd Britten, Dr. Melissa Grimaudo, Dr. John Metz** and **Dr. Jessica Stilley-Mallah**.



Past Presidents of the WCDDA
(L: R) **Dr. Larry Morgan, Dr. Leo Cullinan, Dr. Hugh Wunderlich, Dr. Don Cadle, Dr. Paul Palo, Dr. Paul Miller, Dr. Terry Buckenheimer, Dr. JP** and **Dr. Bob Hart**.



#FLAMOM

WCDDA President-Elect, **Dr. Natalie Carr-Bustillo** (C) and dental colleagues rockin' the Pedo section at the recent FLA-MOM event in Pensacola.



(L: R) **Dr. Christie Eastman Craighead, Mrs. Stephanie Troxler, Dr. Chelsea Brockway** and **Dr. Bobby Troxler** attended the recent Beers with Peers event at Motorworks Brewing in Bradenton.



#2017DDOH

(L: R) **Dr. Greg Langston, Dr. Sandy Worman, Dr. Luis Martinez** and **Dr. Michael Adams** visiting the Florida Legislature in support of Dentists' Day on the Hill.

#SHOWMEYOURSMILE

“TREATING CLIENTS LIKE FAMILY IS JUST SECOND NATURE.

I GREW UP IN MY FATHER’S DENTAL PRACTICE. ”

Not just any broker can say this.



Greg Auerbach, MBA
Greg.Auerbach@HenrySchein.com
727.498.5670

And, not just any broker has this said about him.

“Greg made a very complicated process understandable – always ready to answer any questions or concerns. I truly felt he was my advocate and made the whole experience pain free (important in business as well as dentistry).”

– Greg Dickinson, DDS –
Sarasota

DENTAL PRACTICE SALES | APPRAISALS | PARTNERSHIPS | BUY-INS & BUY-OUTS | MULTI-DOCTOR TRANSITIONS | ASSOCIATESHIPS

ADS Florida

Now a division of Henry Schein Professional Practice Transitions

ADSflorida.com

HENRY SCHEIN®

PROFESSIONAL PRACTICE TRANSITIONS

HenryScheinPPT.com

Dentists' Day on the Hill



As a first year Collier County Dental Association Executive Council member, I had the opportunity to attend Dentists' Day on the Hill for 2017. I did not know what to expect, nor did I understand what our responsibilities were. I did not know the importance of Dentists making a presence in the Capitol.

Dr. TJ Albert and I were selected to represent Collier County Dental Association (CCDA). Dr. Albert is a past President of CCDA and has been to Dentists' Day on the Hill once before. Having an expert lead the way was very comforting. Wow! What I found at Dentists' Day on the Hill was impressive. What a wonderful experience, getting to meet our Senators and Representatives.

We discussed important dental issues such as: Community Water Fluoridation; Donated Dental Services Program; Increase Access to Dental Care in Underserved Areas; and Maintain Educational Standards for Internationally Trained Dentists. Dr. Albert and I also met with Senator Passidomo and Representatives Donalds and Rommel.

In the beginning of 2016, Collier County had a conflict with Fluoridation. Some of Collier County citizens wanted the Commissioners to take fluoride out of our public waters. CCDA came together to fight against this. It is so important that our community gets optimum fluoride in the water. An investment of only \$1 per person saves an average of \$38-\$43 of dental treatments!

Another topic that was discussed is the Donated Dental Services Program to fund full-time coordinators for Donated Dental Services. The funding will be passed through the Department of Health's budget. These coordinators will help hundreds of Florida dentists and Dental Labs to organize free comprehensive treatment and donations for people with disabilities, the elderly and patients that cannot afford dental care.

Federally underserved areas have always been a challenge for access to care. This is especially challenging for new dental graduates, with an enormous amount of student loan debt. The average student loan for a new graduate will range from \$250,000 to \$450,000. In the past, Florida implemented a program that would help dentists in repaying their student loans if they agreed to be a Medicaid provider in an underserved area. In 2016, this legislation was brought up by the Legislature; however it was vetoed by the Governor. If we can get this legislation to pass, this would be a win-win situation for all parties.

Our last topic was Maintain Educational Standards for International Trained Dentists. Currently, the law requires International Trained Dentists to complete 2 years of supplemental general dentistry program before taking the Florida licensure exam. The purpose of the supplemental education program is to ensure that the internationally trained dentists have the same skills and knowledge as our graduates and they are familiar with the oral health care delivery system. In the past, legislators have tried to make a shortcut for internationally trained dentists. If they agreed to practice and treat Medicaid patients they could bypass the supplemental education requirements. The Florida Dental Association supports our current laws that require a supplemental dentistry program for all International Dentists.

In conclusion, my experience of Dentists' Day on the Hill was fantastic. This trip was made possible by the Dan Bertoch Memorial Grant. I really appreciate all of the hard work of the FDA's political team. They were very organized. It is great to be part of our Dental community and to be able to reach out to our citizens and politicians. When we work together and help each other, we make our community a better place. 🇺🇸

-Queanh Phan, DMD



(L-R) Dr. TJ Albert, Senator Kathleen Passidomo and Dr. Queanh Phan

**Save the Date for Dentists' Day on the Hill
February 5-6, 2018!**

To donate to the Dr. Daniel Bertoch Scholarship, mail a check to:
WCDDA, 1114 Kyle Wood Lane, Brandon, FL 33511.
Memo: DDOH Bertoch Scholarship or call (813) 654-2500.

To date: 7 WCDDA members have been sponsored by the scholarship.

Importance of Membership

"LIKE" WCDDA on

facebook



**Don't Delay,
Renew your Dues Today!**
www.FloridaDental.org/dues

These are just a few things tripartite dentistry has to offer. View additional benefits by visiting, www.floridadental.org/docs/default-source/default-document-library/membership-benefits-booklet_0816_web.pdf

For more information about membership, call (800) 260-5277 or visit www.wcdental.org or www.floridadental.org.

- **Protecting the Profession:** Local, state and national lobbying efforts and political representation.
- **Peer Review:** Avoid costly legal fees and malpractice suits by using this free service available only to members.
- **Continuing Education and Licensure Requirements:** High quality continuing education courses at a reduced rate. Courses offered by the association are uploaded into CE Broker for you for an easy license renewal.
- **Practice Enhancement:** FDA Services has researched and vetted business solutions so members can take advantage of exclusive deals and discounts through the Crown Savings program. FDASupplies.com offers deeply discounted dental supplies to members only.
- **Practice Management:** Contract analysis service, compliance with HIPAA and Florida privacy law, legal FAQs and answers, ethics hotline, marketing toolkit and the ADA Center for Practice Success are available to members only.
- **Business and Asset Protection:** FDA Services offers a wide range of insurance that is offered at affordable rates to members.
- **Managed-care Handbook:** You Want Me to Sign What? A Florida Dentist's Handbook on Managed-care Contracts is a comprehensive reference including information on reimbursement, risk, negotiating, and rights and duties of both parties. Request a copy, Kelsey@wcdental.org.
- **Promoting the Profession and Keeping You Informed:** Access to all special events, press releases, social media, ADA/FDA/WCDDA publications and referral sources.
- **Fun Networking Opportunities:** Join your friends and colleagues for fun networking events throughout your district

2017 ~ Mark Your Calendar ~ 2018

WCDDA Executive Cabinet Meeting, Brandon May 19, 2017

*WCDDA Breakfast Lec. Series, Renaissance, Tampa . May 20, 2017

WCDDA Delegation Caucus, Various Sites June 6, 2017

FDC, Gaylord Palms, Orlando June 22-24, 2017

FDA House of Del., Gaylord Palms, Orlando June 23-24, 2017

WCDDA Summer Meeting, Naples Aug. 3-6, 2017

ADA Annual Session, Atlanta, GA Oct. 20-24, 2017

WCDDA Delegation Caucus, Various Sites Jan. 16, 2018

FDA House of Delegates, Tampa Marriott, *tentative* Jan. 26-27, 2018

WCDDA Annual Meeting, CAMLS, Tampa Feb. 2, 2018

Dentists' Day on the Hill, Tallahassee. Feb. 5-6, 2018

FLA-MOM, Lee County Civic Center, Ft. Myers . . . March 9-10, 2018

WCDDA Delegation Caucus, Various Sites June 12, 2018

FDC, Gaylord Palms, Orlando June 21-23, 2018

FDA House of Del., Gaylord Palms, Orlando June 22-23, 2018

WCDDA Summer Meeting, Naples Aug. 3-5, 2018

***New Dentist Event**

COUNT ON YOUR FDAS AGENT

LIKE A MEMBER OF YOUR DENTAL TEAM

We have the knowledge, experience and insurance providers to assure that you have the coverage you need to practice with security and peace of mind.

TRY YOUR AGENT...

- Professional Liability
- Office Overhead
- Individual Health
- Annuities
- Office Package
- Workers Comp
- Life Insurance
- Auto & Boat
- Disability Income
- Group Health
- Long-Term Care
- More...



Rick D'Angelo
Director of Sales

P: 813.475.6948 | F: 813.475.6959
E: rick.dangelo@fdaservices.com



services inc.
FLORIDA DENTAL ASSOCIATION
SM

New Members

The following dentists have recently joined the WCDDA, FDA and ADA! Congratulations and welcome!

Dr. Alex Afsahi, Bradenton
Dr. Anamevys Alonso, Lehigh Acres
Dr. Richard Beatty, Bradenton
Dr. Chelsea Benza, Naples
Dr. Maria Brachowicz, Brandon
Dr. Alexander Brao, Rohnert Park
Dr. Andrew Brattain, Tampa
Dr. Chelsea Brockway, Saint Petersburg
Dr. Keya Brown, Fort Myers
Dr. James Burne, Sarasota
Dr. Oliver Cabrera, Port Charlotte
Dr. Rachel Caldwell, Saint Petersburg
Dr. Juliana Chang, Tampa
Dr. Brandon Cohen, Tampa
Dr. Thomas Crowgey, Lakewood Ranch
Dr. Maridith De Jesus, Land O Lakes
Dr. Amanda del Cueto, Tampa
Dr. Nathan Dewsnap, Naples
Dr. Maria Diaz, Bonita Springs
Dr. Antonio Dohi, Tampa
Dr. Melissa Duston, Port Charlotte
Dr. Joy Eakins, Port Charlotte

Dr. Adam Feldman, Tampa
Dr. Joel Felsenfeld, Lakewood Ranch
Dr. Ross Freeman, University Park
Dr. Elena Gaar, Bonita Springs
Dr. Mikhail Gankin, Riverview
Dr. Jasen Genninger, Temple Terrace
Dr. Laura Goodwin, Tampa
Dr. Benjamin Gubernick, Largo
Dr. Muyeenul Hassan, Bradenton
Dr. George Helmy, Saint Petersburg
Dr. Jerri Hines, Tampa
Dr. Caroline Inaba, Lithia
Dr. Priyanka Iyer, Brandon
Dr. Leah Kanner, Tampa
Dr. Shamus Loftus, Naples
Dr. Jacobson Ma, Pinellas Park
Dr. Aaron Memon, North Port
Dr. Christian Milanes, Fort Myers
Dr. Andrew Minias, Tampa
Dr. Denis Monzin, Bradenton
Dr. Jose Morales Gonzalez, Fort Myers
Dr. Darshan Naidu, Bradenton

Dr. Zara Nensey, Tampa
Dr. Amanda Newcity, Brandon
Dr. Ivelisse Ortiz, Fort Myers
Dr. Kristin Paisley, Lake Wales
Dr. Ricky Pan, New Port Richey
Dr. John Plumley, Saint Petersburg
Dr. Harry Richter, Tampa
Dr. Luis Rodriguez-Riera, Bonita Springs
Dr. Joslyn Rubin, Frostproof
Dr. Prematee Sarwan, Riverview
Dr. Rosalyn Shkolnikov, Brandon
Dr. Janielle Silliman, Sarasota
Dr. Inessa Slipak, Bradenton
Dr. Dilshad Sumar-Lakhani, Palm Harbor
Dr. Mehulkumar Trivedi, Holiday
Dr. Christine Van Groesbeck, Valrico
Dr. Luz Visbal, Wesley Chapel
Dr. Tracy Walters, Sebring
Dr. Lauren Widmer, Cape Coral
Dr. Michael Willis, Dickson
Dr. Peter Worth, Tampa

The following new members have recently reinstated their membership to the tripartite! Thank you and welcome back to organized dentistry!

Dr. John Babcock, Sarasota
Dr. Maryam Bangash, Lake Wales
Dr. Daniel Branca, Brandon
Dr. Mark Bronner, Bonita Springs
Dr. Sara Cervantes, Brandon
Dr. Will Deliz, Tampa
Dr. Shawn Douglas, New Port Richey
Dr. Robin Flicker, Plant City

Dr. Adriana Gabaldon, Naples
Dr. Asta Grinis, St Pete Beach
Dr. Charles Guenther, Port Richey
Dr. Dina Howell, Tampa
Dr. Wayne Kuo, Fort Myers Beach
Dr. Jacob Pedraza, Land O lakes
Dr. Robert Perlstein, Lehigh Acres
Dr. Aleksander Precaj, New Port Richey

Dr. Deanne Rife, Englewood
Dr. Alejandra Romero, Fort Myers
Dr. Wendy Terry, Saint Petersburg
Dr. William Urschel, Venice
Dr. James Wasielewski, Tampa
Dr. Chelsea Wilson, Pinellas Park

In Memoriam

We are deeply saddened by the death of our colleagues.

Ernest Cervis, DMD of Tampa, FL - August 1, 2016 – past president of the WCDDA (1973-1974)

Malcolm Kerstein, DDS of Port Charlotte, FL - August 29, 2016

Marlin Walker, DDS of Seffner, FL - February 20, 2016

Barry Weber, DMD of Spring Hill, FL - January 10, 2017

Robert Williams, Jr, DDS of Lakeland, FL - February 6, 2017

A contribution has been made to the WCDDA Fund in their memory. If you would like to make a contribution, please make your check payable to the Florida Dental Health Foundation, indicate WCDDA Fund in the memo and mail to: Florida Dental Association, Attn: Foundation, 1111 East Tennessee Street. Tallahassee, Florida, 32308-6914.

Annual Summer Meeting Program

THE RITZ-CARLTON, NAPLES

AUGUST 3-6, 2017

REGISTER ONLINE
at wcdental.org

Thursday, August 3rd

The Energy Bus: Creating Positive Leaders
2 CE Credits 9:30 a.m. - 11:30 a.m.
Jim Van Allan

Friday, August 4th

Cycling: No drop ride, all levels welcome 7:00 a.m.

Registration and Exhibits 7:30 a.m. - 12:00 p.m.

Management of Dental Trauma: An Interdisciplinary Approach (1st session)
3 CE Credits 8:00 a.m. - 11:30 a.m.
Dr. Roberta Pileggi

Golf (Location TBD) 9:00 a.m. Shotgun
Fee includes: greens fee, cart, lunch and awards.

Cigars and Cordials 9:00 p.m.
Come join fellow aficionados at our annual Cigars and Cordials event.
(Cigars and cordials are at your own expense)

Saturday, August 5th

5k Fun Run (Free Event) 7:00 a.m.

Registration and Exhibits 7:30 a.m. - 12:00 p.m.

Management of Dental Trauma: An Interdisciplinary Approach (2nd session)
3 CE Credits 8:00 a.m. - 11:30 a.m.
Dr. Roberta Pileggi

Family Fun Live! Check-in between 9:00 a.m. - 11:00 a.m.
Join WCDDA families and friends for a FUN, LIVE commercial video competition. Complete details will be kept top secret until the event starts. TIP: Video features YOU the star and the beautiful venue...
Lights, Camera, Action!

WCDDA Officer Installation 5:00 p.m.
Sponsored in part by: Centennial Bank

Beer, Wine & Cheese Reception 5:30 p.m. - 7:00 p.m.

**Attention
Cyclists!**

No drop ride on Friday & Sunday.
Departing from The Ritz-Carlton at
7:00 a.m., returning prior to CE.
All levels welcome!

Sunday, August 6th

Cycling: No drop ride, all levels welcome 7:00 a.m.

Registration and Exhibits 7:30 a.m. - 12:00 p.m.

Medical Errors in Dentistry
2 CE Credits 8:00 a.m. - 10:00 a.m.
Dr. William Robinson (Mandatory Seminar for Re-Licensure)

Domestic Violence
2 CE Credits 10:30 a.m. - 12:30 p.m.
Dr. Glori Enzor & Special Agent Terry Thomas
(Mandatory Seminar for Re-Licensure)

Location

The Ritz-Carlton, Naples is located at 280 Vanderbilt Beach Road, Naples, FL 34108. Maps can be found online at <http://www.ritzcarlton.com/en/Properties/Naples/>.

Hotel Reservations & Meeting Registration

Reservations can be made online by visiting www.wcdental.org or by contacting The Ritz-Carlton, Naples at (239) 598-3300. Limit 2 rooms per registrant. Request the **West Coast District Dental Association room block rate of \$199.00 per night**. Club level rooms can be secured through the WCDDA office at (813) 654-2500. **Individuals not registered for the meeting will be charged the hotel rack rate instead of the group rate upon checkout.** Registrants desiring more than two rooms may check back after May 31, 2017 at which time if there are still rooms remaining in the group room block, the additional rooms will be made available on a first come basis. CE fees after July 21st increase by \$20.00 per registrant. Pre-registered dentists receive a WCDDA amenity. Refund and Cancellation Policy: All requests for refunds or cancellations must be made in writing to the WCDDA prior to the pre-registration deadline of July 21, 2017. A cancellation/processing fee of 15% will be charged. No refunds will be given if cancellation is received after the pre-registration deadline. No refunds will be given on site. **Questions concerning reservations should be addressed with The Ritz-Carlton, Naples (239) 598-3300. Questions concerning meeting registration should be addressed with the WCDDA office (813) 654-2500.**

Leisure Reservations

For spa, golf or dinner within the hotel, pool and beach cabana reservations please call (239) 514-6001.

Support the WCDDA Fund

Make a donation to support the WCDDA Fund for your chance to win a variety of items that will be raffled throughout the meeting. A complete list of items will be featured in the onsite program. Raffle tickets start at \$5.00. You do not have to be present to win. **You may purchase tickets on the enclosed registration form or online.**

The WCDDA Fund supports local dental health education, access to care projects, careers in dentistry and disaster relief.

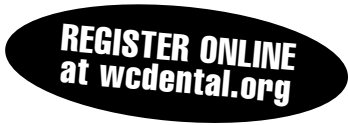

Sneek Peek...

ADA C.E.R.P.® | Continuing Education Recognition Program

WCDDA is an ADA CERP Recognized Provider.
ADA CERP is a service of the American Dental Association to assist dental professionals in identifying quality providers of continuing dental education. ADA CERP does not approve or endorse individual courses or instructors, nor does it imply acceptance of credit hours by boards of dentistry.

**West Coast District Dental Association
Annual Summer Meeting - Registration Form
August 3-6, 2017**



Please Print Clearly

Name of Registering Dentist: _____ Phone: _____

Address: _____ City: _____ State: _____ Zip: _____

Email: _____ ADA #: _____ License #: _____

Staff Name: _____ Staff Name: _____ Staff Name: _____

<input type="checkbox"/> CE Fees All Inclusive:	<input type="checkbox"/> MEMBER \$250.00 (WCDDA, FDA, ADA)	<input type="checkbox"/> NON-MEMBER \$390.00	<input type="checkbox"/> RESIDENT/STUDENT FREE
	<input type="checkbox"/> RETIRED MEMBERS \$50.00	<input type="checkbox"/> STAFF \$50.00	

Thursday, August 3rd
.....

9:30 a.m. The Energy Bus: Creating Positive Leaders No. of attendees _____

Friday, August 4th
.....

7:00 a.m. Cycling (All levels welcome) Free No. of riders _____

8:00 a.m. Management of Dental Trauma: An Interdisciplinary Approach (1st Session) No. of attendees _____

9:00 a.m. Golf (Location TBD). \$125.00/Player No. of players _____ x \$125.00 = \$ _____

Golfer(s) & Handicap: _____

9:00 p.m. Cigars & Cordials. At your own expense No. of attendees _____

Saturday, August 5th
.....

7:00 a.m. Fun Run. Free No. of runners _____

8:00 a.m. Management of Dental Trauma (2nd Session) No. of attendees _____

Family Fun Live! Free No. of attendees _____

5:00 p.m. Officer Installation. Free No. of attendees _____

5:30 p.m. Beer, Wine & Cheese Reception Free No. of attendees _____

Sunday, August 6th
.....

7:00 a.m. Cycling (All levels welcome) Free No. of riders _____

8:00 a.m. Medical Errors in Dentistry No. of attendees _____

10:30 a.m. Domestic Violence No. of attendees _____

Raffle Tickets: 1 for \$5.00 – 10 for \$25.00 – 25 for \$50.00 No. of tickets _____ \$ _____

Registration + Events **TOTAL** \$ _____

Payment Method: Check: Made payable to WCDDA Visa MasterCard Amex

Credit Card No.: _____ Exp. Date: _____ CVV Code: _____

Signature: _____ Billing Zip Code: _____

Please mail or fax this form to the WCDDA:
1114 Kyle Wood Lane • Brandon, FL 33511 • (813) 654-2500 Fax (813) 654-2505



Association Business - Official Calls

There will be a caucus of the West Coast District Dental Association's Delegation on Tuesday, June 6, 2017 at 6:00 p.m. via conference call. There will be twelve sites throughout the West Coast district.

The West Coast District Dental Association will hold a breakfast caucus in conjunction with the Florida Dental Association's House of Delegates meeting Saturday, June 24, 2017 at 7:00 a.m. at the Gaylord Palms, Orlando 🇺🇸

Dr. Reza Iranmanesh
WCDDA Secretary

You're Invited

2017-2018

West Coast District Dental Association's Officer Installation

Saturday, August 5, 2017 at 5:00 p.m.

The Ritz-Carlton, Naples

In conjunction with the

West Coast District Dental Association's

2017 Summer Meeting

Important Information

The Americans with Disabilities Act Website Accessibility

The Americans with Disabilities Act (AwDA) requires that places of public accommodation, including physicians' and dentists' offices, be accessible to persons with disabilities. With the advent of the internet, and of websites that businesses use to provide additional access to the public, the U.S. Department of Justice has taken the position that websites open to the public also must be accessible in various ways to persons with sight or hearing impairment. This interpretation may affect not only the websites of our members, but also those of our associations themselves. You may be aware that several member dentists in Texas have received letters from attorneys alleging that their websites violate the AwDA because the websites are not accessible to individuals with disabilities. The letters typically request the payment of some amount of money to avoid a lawsuit, and also may insist on prompt compliance with the law. As it is possible that other member dentists may receive similar letters, we thought some guidance might be helpful.

To assist both the members and the state associations with this issue, the ADA has prepared the following documents:

A quick rundown, in a brief, executive summary-type format, of steps that members should consider in the short term to make their websites less susceptible to a claim. Visit, <http://wcdental.org/WebsiteAccess01.pdf>.

A "white paper" type document that describes in greater detail strategies for members (and their attorneys) in case they receive a demand letter of the type described above. The paper also includes the actions that members might consider to make their websites more fully accessible to persons with disabilities in the long term. Visit, <http://wcdental.org/WebsiteAccess02.pdf>.

For FDA members that use Officite as their website developer, their customer service team will work with each individual practice to address ADA questions or issues related to their specific website. Officite can run a website accessibility scan in an effort to correct any identified issues.

Severe Cervicofacial Emphysema and Pneumomediastinum Caused by a Dental Handpiece

A Case Report and Guidelines for Management for the Dental Practitioner

Christopher Ban, D.M.D.; Armando Uribe-Rivera, D.D.S.; Deepak Krishnan, D.D.S.

ABSTRACT

Cervicofacial emphysema (CE) is a rare but potentially serious condition that can arise iatrogenically from dental or surgical procedures. Dental handpieces with fore-exhaust can inject air into tissues at pressures at or greater than 30 psi. Since 1963, there have been approximately 100 case reports in the literature of iatrogenic CE from routine dental procedures. Prompt recognition and treatment are essential; however, many general practitioners may only be familiar with CE from their dental school curriculum. A case of unusually severe cervicofacial emphysema with concomitant pneumomediastinum is presented, along with a discussion and review of management principles for the general dentist. It is our hope that refamiliarization with this condition will give the general dentist an appreciation for and recognition of signs of CE, thereby being the first link in a chain of successful treatment.

Cervicofacial emphysema (CE), or air forced into subcutaneous tissue planes, is a rare but potentially serious condition that can arise secondary to trauma or pathology and, even more rarely, iatrogenically from dental or surgical procedures. CE subsequent to dental procedures is not a new phenomenon, being described as early as 1900 by Turnbull.¹ Since 1963, there have been approximately 100 case reports in the literature of iatrogenic CE from dental procedures. Although iatrogenic CE can arise from increased intraoral pressure after the procedure (e.g., coughing, sneezing, vomiting), a large number result from the use of a high-speed dental handpiece or air/water syringe.^{2,3,4}

Signs and symptoms of CE and pneumomediastinum (air in the midline thorax) are variable, as are times to onset. Indeed, many patients do not seek care for hours or even days after the causative incident. The condition is frequently misdiagnosed on presentation, but, as will be shown, it is easily differentiable. Severe complications, while rare, have been reported and include death due to respiratory and cardiac complications. Early detection and treatment are, therefore, essential.^{7,12,13}

A severe case of iatrogenic CE complicated by pneumomediastinum from use of a dental handpiece is presented, along with a review of the literature and consideration of varying presentations and treatments.

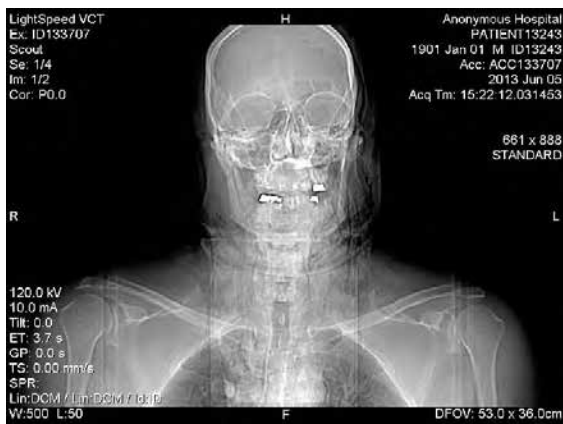

Figure 1. Anterior-posterior cephalometric film. Attempted extraction site in posterior left mandible is seen, with removal of bone evident around root of previously endodontically treated tooth.

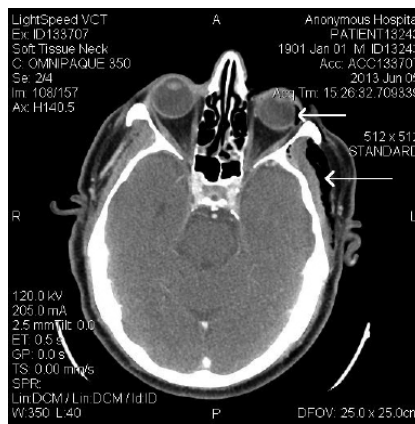


Figure 2. Axial CT slice at level of eye. Air (indicated by dark black areas) is evident in left orbit and left temporal regions.

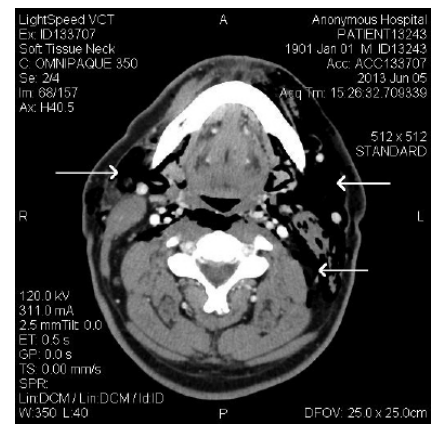

Figure 3. Axial CT slice at level of mandibular angle. Diffuse collections of subcutaneous and subfascial air are seen bilaterally in area of mandibular angles and masseteric spaces.

Case Report

A 56-year-old man of Middle Eastern descent presented to the emergency department via EMS escort from his general dentist's office. From the patient's report, the general dentist had attempted surgical extraction of the lower left third molar tooth with a high-speed handpiece. Upon attempted sectioning of the tooth, the patient developed immediate pain and a rapidly progressing swelling to the left side of his face and neck, leading the dentist to terminate the procedure and activate emergency response.

Upon arrival at the emergency department, the oral and maxillofacial surgery service was consulted. The patient's vitals were BP 142/79, Pulse 95, RR 16, SpO₂ 100%. Head and neck exam revealed redness and swelling around the entire lower third of the patient's face and neck, behind his neck and surrounding his left eye. All areas of swelling were noted to have crepitus (often described as sounding and feeling like "rice krispies") on palpation, suggesting subcutaneous air. There was no actively draining pus or bleeding. Intraoral examination showed that tooth #17 was grossly carious and had been sectioned without evidence of creation or elevation of a flap. A complete blood count was normal, ruling out an infection. The patient's past medical history was significant for hypertension, Type I diabetes mellitus and obstructive sleep apnea.

Given the patient's recent history of attempted surgical extraction with dental handpiece, immediate swelling and physical exam, a diagnosis of cervicofacial emphysema was made.

The patient underwent a CT scan, which revealed pneumomediastinum with air inclusions surrounding the great vessels of the heart, the deep and superficial spaces of the neck, bilateral submandibular and buccal spaces, left canine space, and the left ear and posterior head.

The patient was placed on 8L O₂/min for the first 12 hours and IV antibiotics (ampicillin plus sulbactam 3g q8h for 72 hours) for prophylaxis for potential oral pathogens that could have been deeply seeded by the pressurized air.

By hospital day three, CT showed attenuation of all air pockets. He was otherwise stable throughout his entire hospital stay. The patient was discharged on augmentin 875mg and oxycodone-acetaminophen 5/325.

At follow-up in our clinic one week after his initial admission, the emphysema had completely resolved.

Discussion

Cervicofacial emphysema is caused by the entrance of air into the soft tissues of the head and neck. Once access to these subfascial planes occurs, dental handpieces with fore-exhaust can inject air into tissues at pressures at or greater than 30 psi.^{2,14} This can occur during routine restorative, endodontic and periodontal procedures, but it is most often due to the use of pressurized air during surgical extractions. Air travels a path of least resistance, dissecting through the various spaces of the head and neck. In a review of 47 cases by Arai, et al. of dental iatrogenic CE, 38 were associated with the use of a high-speed, air-driven handpiece or air/water syringe. Also of note in these cases is that 39 of 47 were associated with mandibular molars.⁹ In the posterior mandible, air can dissect through the submandibular and parapharyngeal spaces to the retropharyngeal space, thereby reaching the mediastinum and other structures of the thorax.

The signs and symptoms of CE vary. Although the patient in the reported case, like 90% of CE cases, exhibited immediate onset of pain and swelling, many cases present without pain and may take hours to days to manifest.^{9,16} In addition to pain and swelling, patients may present with difficulty swallowing and vision changes.⁷ The diagnostic sign associated with CE is crepitus to palpation of the involved portions of the head and neck. Mediastinal air is marked by so-called "brassy voice," difficulty breathing, chest and/or back pain, and Hamman's sign—crepitus during systole heard with aid of a stethoscope.¹⁵ EKG changes may be present in approximately 25% of patients.^{10,14} Plain film radiographs, such as

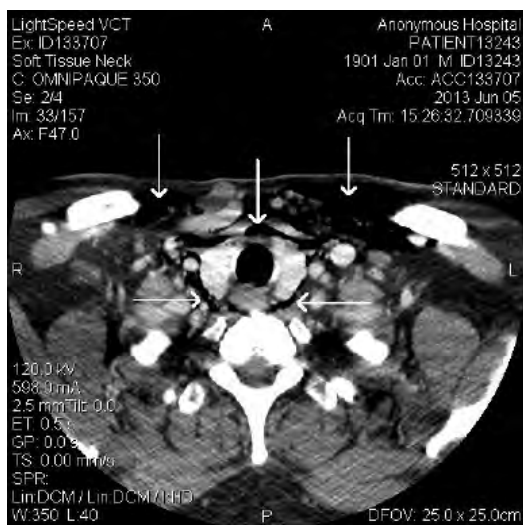


Figure 4. Axial CT slice at level of clavicles. Air is seen circumferentially around trachea. Diffuse air inclusions are seen subcutaneously and in pretracheal space.

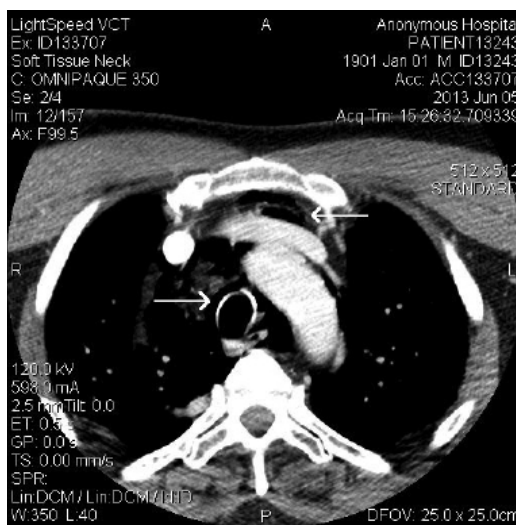


Figure 5. Axial CT slice at level of manubrium. Air inclusions are seen within mediastinum, around great vessels of heart and trachea.



Figure 6. Clinical photo of patient immediately after attempted extraction and onset of emphysema.

panoramic X-rays, may aid in diagnosis; however, once deep anatomical space involvement is suspected, hospital-grade CT is indicated to determine the extent of the emphysema.

Differential diagnosis for CE includes allergic reaction, angioedema and infection. Indeed, allergic reaction is a common misdiagnosis in cases of iatrogenic CE from dental procedures, causing administration of unnecessary medications (e.g., corticosteroids) in the dental office or the emergency room.⁴ A complete history with consideration of precipitating events should easily distinguish a case for CE. CE and pneumomediastinum have been associated with reports, albeit rare, of death due to respiratory and cardiac complications.¹² Thus, once CE is suspected, immediate referral to the emergency department is warranted.

Treatment for CE and pneumomediastinum consists of hospital admission with monitoring of respiratory and cardiac function, while decreasing discomfort with appropriate analgesics.⁵ Respiratory function can be severely impaired, with some patients requiring tracheotomy. Length of hospital stay can range from as little as 24 hours to 6 days before complete amelioration of symptoms.^{4,5,9}

While there are few infections in the literature arising from iatrogenic CE, there is concern for serious infection and associated complications, such as necrotizing fasciitis.^{5,8,18} Antibiotic prophylaxis seems reasonable, given that the air driven into tissues almost certainly carries with it the normally occurring pathogens present in the oral flora.⁴ Of additional concern is the recent finding of pathogens such as *Klebsiella*, *Legionella* and *Pseudomonas*, present in anywhere from 3% to 10% of dental unit water.^{6,16} However, it is worth noting that both Shovelton in 1957 and Heyman and Babayof in 1995 noted no infection arising in patients who were not administered antibiotics for CE as a result of dental procedures.^{2,11} The use of antibiotics, therefore, may be best considered on a case-by-case basis, given the history of illness and the patient's comorbidities and immune status.

Corticosteroids have a sporadic history of use in cases of CE and pneumomediastinum, and are directed toward treating an incorrectly diagnosed allergic reaction, treating an associated injury or minimizing the extent of airway swelling.⁸ As noted above, due to concern for potentially serious infection in avascular planes, these may be contraindicated and probably best used sparingly and judiciously.

The rarity of iatrogenic CE, and consequent lack of consensus in treatment, has led to varying and speculative modes for adjunctive therapy. Air in tissue emphysema normally is resorbed or released from tissues via diffusion, anywhere from 3 to 10 days after initial embolus.³ Incision and drainage is not typically indicated in tissue emphysema; however, in at least one particularly severe case, a patient benefited from surgical release of entrapped air.¹⁷

Repeat or serial CT has also seen episodic use.^{8,9} In the case of confirmed CE, the benefit of this practice is unclear to these authors. It seems unnecessary to expose the patient to a significant dose of radiation in the absence of clinical symptoms and abnormal lab values. As noted above, resolution of emphysema can be expected within one to two weeks and can be reasonably ascertained by a normal follow-up exam.

Conclusion

The key to effective treatment of iatrogenic CE and pneumomediastinum is prompt recognition. Consequently, the astute general dentist will have an appreciation for and recognition of signs of CE, thereby being the first link in a chain of successful treatment.

While permanent morbidity and mortality are exceedingly rare, potentially serious complications are obvious. While few infections have arisen from iatrogenic CE and pneumomediastinum, even in the absence of antibiotics, the potential severity of such an infection may indicate early administration of prophylactic antibiotics with close monitoring of the clinical course. Continuous cardiac monitoring is indicated. Adjunctive therapy and procedures,

including delivery of 100% oxygen or incision and drainage, are worth considering on an individual basis. Repeat CT and administration of corticosteroids are likely unnecessary in most cases, but may be indicated during observation of the clinical course in patients who fail to improve during hospital admission. //

Queries about this article can be sent to Dr. Ban at christopherban@gmail.com.

REFERENCES

1. Turnbull A. A remarkable coincidence in dental surgery. *Br Med J* 1900;1:1131 (letter).
2. Heyman SN, Babayof I. Emphysematous complications in dentistry, 1960-1993: an illustrative case and review of the literature. *Quintessence Int* 1995 Aug;26(8):535-43.
3. McKenzie WS, Rosenberg M. Iatrogenic subcutaneous emphysema of dental and surgical origin: a literature review. *J Oral Maxillofac Surg* 2009 Jun;67(6):1265-8.
4. Karras SC, Sexton JJ. Cervicofacial and mediastinal emphysema as the result of a dental procedure. *J Emer Med* 1996;14(1):9-13.
5. Elia F, Laface B, Pagnozzi F, Bocuzzi A, Ferrari G, Perna M, Apra F. Cervicofacial emphysema and pneumomediastinum complicating a dental procedure. *J Emer Med* 2013. Nov;45(5):e179-81.
6. Bednarsh HS, Eklund KJ, Mills S. Dental unit waterlines: check your dental unit water IQ. *Access* 1997;10(9). Retrieved from <http://www.osap.org/displaycommon.cfm?an=18subarticlenbr=34>.
7. Buckley MJ, Turvey TA, Schumann SP, Grimson BS. Orbital emphysema causing vision loss after a dental extraction. *JADA* 1990;120:421-4.
8. Patel N, Lazow SK, Berger J. Cervicofacial subcutaneous emphysema: case report and review of literature. *J Oral Maxillofac Surg* 2010 Aug;68(8):1976-82.
9. Arai I, Aoki T, Yamazaki H, Ota Y, Kaneko A. Pneumomediastinum and subcutaneous emphysema after dental extraction detected incidentally by regular medical checkup: a case report. *Oral Surg Oral Med Oral Path Oral Radiol Endod* 2009 Apr;107(4):e33-8.
10. Gray JM, Hanson GC. Mediastinal emphysema: aetiology, diagnosis and treatment. *Thorax* 1966;21:325-32.
11. Shelovelt DS. Surgical emphysema as a complication of dental operations. *Br Dent J* 1957;102:125-129.
12. Aragon SB, Dolwick MF, Buckley S. Pneumomediastinum and subcutaneous cervical emphysema during third molar extraction under general anesthesia. *J Oral Maxillofac Surg* 1986;44:141-4.
13. Goodnight JW, Sercarz JA, Wang MB. Cervicofacial and mediastinal emphysema secondary to third molar extraction. *Head Neck* 1994;16:287-90.
14. Capes JO, Salon JM, Wells DL. Bilateral cervicofacial, axillary, and anterior mediastinal emphysema: a rare complication of third molar extraction. *J Oral Maxillofac Surg* 1999;57:996-999.
15. Hamman L. Spontaneous mediastinal emphysema. *Bull Johns Hopkins Hosp* 1961;54:46-56.
16. Bilecenoglu B, Onul M, Altay OT, Saku BU. Cervicofacial emphysema after dental treatment with emphasis on the anatomy of the cervical fascia. *J Craniofac Surg* Nov 2012;23(6):e544-8.
17. Kung J, Chuang F, Hsu K, Shih Y, Chen C, Huang I. Extensive subcutaneous emphysema after extraction of a mandibular third molar: a case report. *Kaohsiung J Med Sci* 2009;25:562-6.
18. Ely EW, Stump TE, Hudspeth AS, et al. Thoracic complications of dental surgical procedures: hazards of the dental drill. *Am J Med* 1993;95:456.



Dr. Ban



Dr. Uribe-Rivera



Dr. Krishnan

Christopher Ban, D.M.D., is former chief resident, Department of Oral & Maxillofacial Surgery, University of Cincinnati Holmes Hospital, Cincinnati, OH. He is in private practice in oral surgery in Pittsburgh, PA.

Armando Uribe-Rivera, D.D.S., is a former research fellow, Department of Oral & Maxillofacial Surgery, University of Cincinnati Holmes Hospital, Cincinnati, OH.

Deepak Krishnan, D.D.S., is program director, Department of Oral & Maxillofacial Surgery, University of Cincinnati Holmes Hospital, Cincinnati, OH.

FREE PRACTICE APPRAISAL

Visit our website at www.AFTCO.net or call
800.232.3826

TRANSITION CONSULTANTS

Since 1968

FREE PRACTICE APPRAISAL

(\$5,000 value)

CAN BE USED FOR:

- Practice Sales
- Partnerships
- Second Opinions
- Insurance Coverage
- Personal Net Worth
- Retirement Planning

Practice Sales & Purchases Over \$3.2 Billion!

SMALL BUSINESS LOANS

made easy

Centennial Bank can help you choose from options to support your small business in a BIG way.

U.S. Small Business Administration (SBA) and USDA Programs

The U.S. Small Business Administration (SBA) and the USDA offer a variety of loan programs to meet your needs. Call or visit our website to learn more about any of the following SBA and USDA Programs:

SBA Advantage Loan Program	SBA CapLine
SBA Express/LOC	SBA Grow Loan Program
SBA Veteran's Advantage* (1% SBA Fee)	USDA B&I Program (Rural)
Small Loan Advantage (SLA)	USDA Agricultural Program (Rural)

Eligibility & Restrictions

The SBA Programs are for US Citizens or Permanent Resident Aliens (must provide proof), and Owner-occupied and Owner-operated businesses (not for investment or non-profit businesses). Applicants must have a minimum 10% cash, or equity injection (may require additional capital), good credit history (business & personal), capability (must have industry experience and proper licenses when applicable by State Statutes), and commitment (must be willing to sign a personal guarantee and pledge personal assets, if available). For the USDA Programs, borrowers/business must be located in a Rural Area (per the site map on the USDA website).

SBA ADVANTAGE LOAN* PROGRAM and USDA B&I** PROGRAM FINANCING OPTIONS

- Business Acquisition (Goodwill)
- Partner Buy-out (100%)
- Purchase, Refi or Expand/Renovate Owner Occupied Commercial Real Estate (51% minimum occupancy)
- Leasehold Improvements/Renovations
- Purchase or Refi Furniture, Fixtures, Equipment
- Working Capital
- Interim Interest thru Construction, Soft Costs, Closing Costs (100% financed into loan amount)
- Refinance existing business debts
- Construction of Owner-Occupied Commercial Real Estate (80% minimum occupancy)

*SBA Advantage Loan Program has up to 25 year terms (15 year term or more has a 3 year prepayment penalty)

**USDA B&I Program has up to 30 year terms (real estate has a 5 year prepayment penalty)

SBA GROW LOAN PROGRAM FINANCING OPTIONS:

- Purchase or Renovate/Expand Owner-occupied commercial real estate (51% minimum occupancy)
- Purchase Heavy Duty Equipment (Machinery & Equipment)
- Construction of owner-occupied commercial real estate (80% minimum occupancy)

Equipment has a 7 year prepayment penalty and Real Estate has a 10 year prepayment penalty



For more information or to apply, contact:
Tammy Youst • 813-749-5344
SVP/SBA & USDA Dept. Manager
Centennial Bank
18311 U.S. Hwy. 41 North
Lutz, FL 33549
TYOUST@MY100BANK.COM

MY100BANK.COM • A Home BancShares Company (Nasdaq: HQM)



West Coast District Dental Association's Breakfast Lecture Series

Are you?...

- A recent graduate of dental school within the last 10 years?
- Entering or renewing contracts with insurance companies?
- Looking to protect yourself or your practice by managing risk?

This course will help you...

- ✓ Learn how to manage risk.
- ✓ Learn how to protect yourself.
- ✓ Learn essential information when considering contracts.

Insurance for You and Your Practice – Insurance and Risk Management, Mr. Rick D'Angelo and Negotiating with Managed Care Providers – Considerations for Entering or Renewing a Managed-Care Contract, Attorney Frank N. Genco

Saturday, May 20, 2017 | 8:00 a.m. – 11:00 a.m.
Breakfast will be included.

RENAISSANCE TAMPA INTERNATIONAL PLAZA HOTEL
International Plaza and Bay Street | 4200 Jim Walter Blvd., Tampa, FL 33607

\$10.00 fee to attend the breakfast lecture.

Contact Kelsey Bulnes at Kelsey@wcdental.org or
(813) 654-2500 for additional information.



Tailored financial solutions for your dental practice.

TD Bank Healthcare Practice Solutions Group

To see how we can help your practice, contact Drew Holst, Relationship Manager, at 813-250-3063 or Drew.Holst@td.com



America's Most Convenient Bank®

Member **FDIC** TD Bank, N.A.



WEST COAST
DISTRICT DENTAL ASSOCIATION

A COMPONENT OF THE
AMERICAN & FLORIDA DENTAL ASSOCIATIONS

2018

ANNUAL MEETING February 2, 2018

Dr. Stanley Malamed – Emergency Medicine

Larry Guzzardo – Now What Do I Say? and Unravel the Mystery of Treatment Acceptance: A Dental Team's Guide



Bring Your Team!

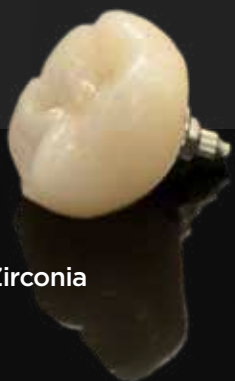

CAMLS: Center for Advanced
Medical Learning and Simulation
Downtown Tampa

SIMPLICITY™

Screw Retained Zirconia

\$279
EVERYDAY
LOW-PRICE



Includes:

- Soft Tissue Model
- Your choice of Solid Zirconia
- Design & Labor
- Screw & Parts

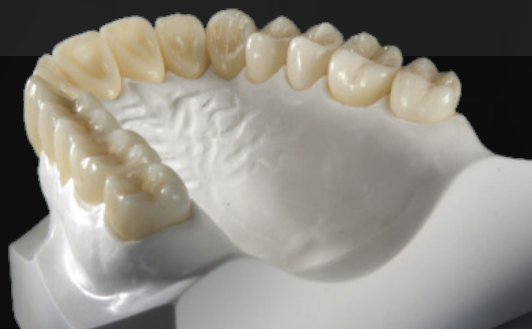Warranty Covers:

- 5 year warranty for crown
- Lifetime warranty on all parts



STARTING AT:
\$89

Solid, Anterior, Plus
or Layered Zirconia



STATE-OF-THE-ART
MILLING CENTER

Clinically Proven,

BAYFLEX™

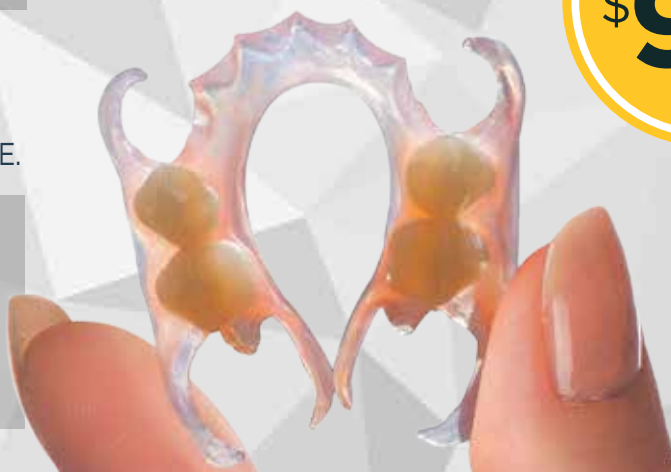PARTIALS

INVISIBLE. COMFORTABLE. AFFORDABLE.

93%

**Gordon J. Christensen
Clinicians Report***

*An independent, non-profit, dental education and product testing foundation, Clinicians Report®, Jan 2014. For the full report, visit <http://bayshoredentalstudio.com/clinicians-report.pdf>



STARTING AT:
\$99



BAYSHORE
DENTAL STUDIO

CALL 877-620-1668

BayshoreDentalStudio.com

CLASSIFIEDS

Volunteers Needed:

Volunteer dentists are needed at the Good Samaritan Clinic. Please contact Teri Averill at (727) 848-7789 ext. 233 for more information or visit www.goodsamclinic.org.

Space for Lease:

New Port Richey, FL (across from hospital) 6 room corner office with setup for an x-ray unit, set ups for three sinks. Rent is \$695 per month for 1,025 sq ft. Contact Elia Ronchetti, DC (owner) at 570-824-8786 or 570-262-0163.

Dental Office for Lease:

Lease by the Operatory, lease by the day. 1-9 operatories, great for specialists, GP's, new grads or associates looking to start their own office. Growing area in Trinity. Equipment available. Instant office, prime location, signage available. Call (813) 480-1637 or email bruce@doylemcgrath.com.

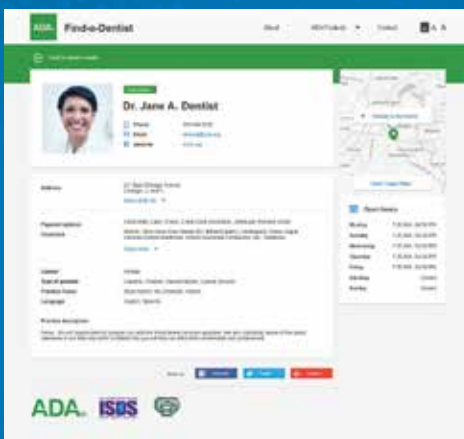Office Space to Share:

Tarpon/Palm Harbor. Modern, Eaglesoft, CEREC, Digital X-Ray and Panoramic, Bien Air electric hand pieces. Ideal for GP or Specialist satellite. Contact, Michael Sampson, DMD (239) 269-5172.

Seeking a Full Time General Dentist in Hernando County:

Family Dentistry of Hernando (352) 596-7388. Founded in 1987 Family Dentistry of Hernando is an established multi-specialty group practice with 2 offices conveniently located in Spring Hill and Brooksville. We are seeking a full-time General Dentist to join our thriving practice. We provide our patients a complete range of dental services, including general dentistry, cosmetic dentistry, endodontic services, restorative and periodontal dentistry, as well as oral surgery. Our highly valued associates enjoy top tier compensation. Come grow with us. For more information on this position, contact: tammy@familydentistryhc.com.

Fill a Form, Fill a Chair



ADA American Dental Association®

You told the ADA you wanted to see more patients, so this spring, we are launching an enhanced Find-a-Dentist tool to help new patients find you.

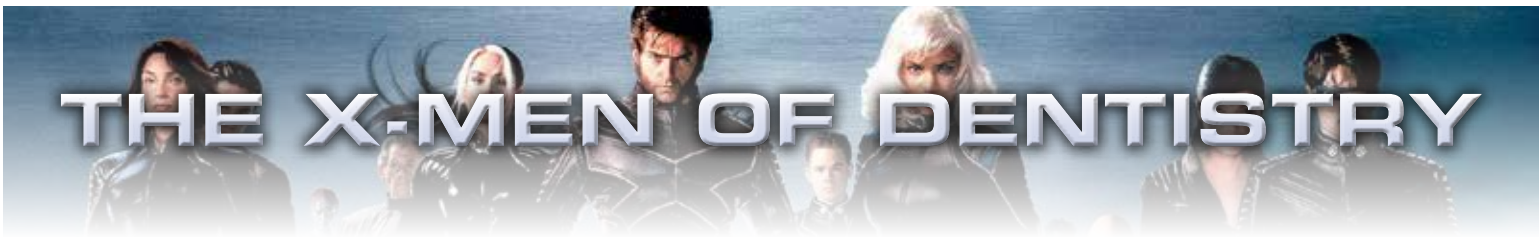By taking 5 minutes to update your member profile, patients can more easily search by geography, specialty and payment and benefit plans. The new tool also prioritizes completed profiles in the search results, and you will have the ability to track how many views your profile receives.

Complete your ADA® Find-a-Dentist™ profile by **May 1, 2017** to be entered for a chance to win a Mercedes Benz C class sedan or GLC SUV 12-month lease or \$10,000 cash award!*



Login to complete your profile for the chance to win!

*All active licensed members practicing in the U.S. are eligible to win. Visit ADA.org/fadrules for official rules.



Whom do you most admire - Pete Dawson, L.D. Pankey, Olivia Munn? Wait...what...Olivia Munn? Spoiler alert she is an attractive actress and one of the X-Men in a movie of the same name. Since Shania Twain and Shakira have never returned my calls, I have moved on to a hopefully more receptive Olivia Munn. My wife tolerates these distractions with understandable doubt. To illustrate this I recall a moment my wife and I shared over Sunday morning coffee and eggs.

"I see Olivia Munn is in Tampa for a project...and if she shows up on our doorstep with a beckoning finger...I may have to leave with her."

"That's fine dear", she countered without even looking away from the Perspective Section of the Tampa Bay Times that shielded her blunt opinion.

How ironic.

Of course I never got the beckoning finger. And of course the X-Men with their mutant superpowers are not real. Too bad, I could use them from time to time. But maybe we CAN learn something from them. The X-Men are a collection of mutants with unique superpowers such that they are ineffective without working together. Nearly every day at work, I struggle with a difficult case or condition. Not exactly a DC comic villain but still I still need help against this evil. Sadly the Xavier House of mutants is not real but fortunately the WCDDA office is the dental equivalent. The staff of the WCDDA can guide you to find the "superpower" that you need. I am a member of the ADA, FDA and WCDDA and as such have access to a world of benefits. I am surrounded by dental specialists that have unique and focused "superpowers". Think about it. They have lasers, microscopic and 3-D vision. These are skills and tools you likely do not have. All to make you look like a hero. Those difficult patients are not best served by one dentist but rather a team of "superheroes". Get to know the X-Men in your area and find out their unique skills. Now if only they could look like Olivia Munn.

- Hugh Wunderlich, DDS



Doctor's Choice Companies, Inc

LET'S TALK ! 561-746-2102

FLORIDA'S LEADER IN PRACTICE SALES

 J. Kenny Jones President/Broker	 Dr. Jack Saxonhouse Palm Beach County	 Morcie Smith CFP West Coast	 Mary Ann Serkin Northrast/Central	 Deanna Eiss Central Florida	 Curtis Johnson Equipment Appraisals	 Dr. Chip Kilcourse Central, FL	 Dr. Marshall Berger Broward County
 Dr. Jerry Pyser Southwest	 Dr. Alex Cardounel Southeast	 Dr. Tony Hodge Treasure Coast	 Dr. Carlton Schwartz Northwest	 Ron Rubenstein Practice Sales	 Melanie Aranda Associate Placement	 Greg Jones Real Estate Sales Leasing &	 Samantha Jones Executive Secretary



**FOR INFORMATION ON OPPORTUNITIES
CALL OR VISIT OUR WEBSITE**

www.doctorschoice1.net

561-746-2102

Services

- * Practice Sales and Purchases
- * Pre-Retirement Strategy
- * Practice Appraisals
- * Associate Placement (Buy-In's)
- * Commercial Property Sales/Leasing
- * Investment Real Estate



WEST COAST DISTRICT DENTAL ASSOCIATION

A COMPONENT OF THE AMERICAN & FLORIDA DENTAL ASSOCIATIONS

1114 Kyle Wood Lane
Brandon, FL 33511
(813) 654-2500 Fax (813) 654-2505
lissette@wcdental.org
www.wcdental.org

PRESORTED
STANDARD
U.S. POSTAGE
PAID
TAMPA, FL
PERMIT NO 3239

Mission:
Helping Members Succeed

Values:
*Service, Commitment,
Integrity and Excellence*

Culture:
*The Reliable Resource
for Dentists.*

The WCDDA Newsletter is published two times a year, in the Fall and the Spring. The Editor of the association and staff organize, print and mail to membership. The position of the editor is elected by the Executive Cabinet and does not have a specified term. The editorial staff holds the right to deny ads submitted for publishing. The newsletter may publish signed articles relating to all phases of dentistry, but assumes no responsibility for opinions expressed by the contributors. Publication in this newsletter does not imply the West Coast District Dental Association endorses any products or services that are advertised. Views, editorials, news columns and/or articles are those of the author's and not necessarily of the editor, staff, or members of the West Coast District Dental Association.

EDITOR
Hugh Wunderlich, DDS, CDE

CO-EDITOR
Oscar Menendez, DDS

MANAGING EDITOR
Kelsey Bulnes

EXECUTIVE DIRECTOR
Lissette Zuknick

THE WEST COAST DISTRICT
DENTAL ASSOCIATION
serves these counties:

Charlotte	Hardee	Manatee
Citrus	Hendry	Pasco
Collier	Hernando	Pinellas
DeSoto	Highlands	Polk
Glades	Hillsborough	Sarasota
	Lee	

NEW!
NOW RECRUITING
MEMBER DENTISTS
TO MENTOR.

fda mentorship program

What is the FDA Mentorship Program?
The Florida Dental Association (FDA) Mentorship Program was developed by the FDA Council on the New Dentist as a resource to help dental students gain a practical and professional perspective from established member dentists.

Who Participates?
The mentors are FDA member dentists who volunteer their time and experience to provide professional guidance to dental students. All member dentists are encouraged to participate as mentors. A select number of dental students (depending on the number of mentors available) from each Florida dental school (IECOM, Nova and UFCD) will be able to participate as mentees.

What Does It Involve?
The online mentoring program has been designed with the needs of the student and busy dentist in mind.

Connecting is easy:

1. Member dentists can volunteer by completing a quick and easy online form at floridadental.org/mentors.
2. The mentee will select a mentor from the bios available at floridadental.org.
3. The mentee will contact the mentor directly via email.
4. The mentor will contact the FDA Director of Member Relations, Kerry Gomez-Rios, to inform the FDA that he/she has accepted a mentee.

If at any time a change in the mentor/mentee relationship is needed, please contact Kerry Gomez-Rios at membership@floridadental.org.

Questions?
For more information, contact Kerry Gomez-Rios at membership@floridadental.org.



A busy schedule shouldn't get in the way of a plan for your future.



Kirk L. Gravelle CFP®, CIMA®
Senior Investment Management Consultant
First Vice President
Financial Advisor

50 N Laura St
Jacksonville, FL 32202
904-665-0453
kirk.gravelle@morganstanley.com
www.morganstanleyfa.com/kirk.gravelle

It's easy to lose track of your financial plan when your days are filled with other responsibilities. As a Morgan Stanley Financial Advisor, I can work with you to understand your goals and help you create an investment strategy that's right for you. With your future on track, you can focus on all that's happening in your life now. Call me today to learn more.

Morgan Stanley