

Checkup

Volume 49 • Issue 1 • Spring 2019



WEST COAST
DISTRICT DENTAL ASSOCIATION

A COMPONENT OF THE
AMERICAN & FLORIDA DENTAL ASSOCIATIONS



Mission: Helping Members Succeed

Culture: The Reliable Resource for Dentists

Values: Service, Commitment, Integrity and Excellence

**Back to the Ritz!
Details Inside!**

President's Message



Dr. Oscar Menendez
President

Saludos WCDDA Members,

Having been born in Cuba and raised in Florida, I thought I would throw in some of my ethnicity in the greeting. My year as President has been flying by and it is incredible that we are already half way through it. It has truly been a pleasure visiting the different affiliates and having an opportunity to interact with the members.

I hope everyone had a great holiday and were able to enjoy their families. As many of you with adult children know, it gets more and more difficult to spend that time with the ones you love. So make sure you enjoy those special moments.

I personally hit the road running in January, going to 4 different affiliate meetings; Polk County, Upper Pinellas County, Hernando County and West Pasco County Dental Associations. Throw in the House of Delegates Caucus call, House of Delegates, Mission of Mercy site visit in Orlando, FDA Foundation Emerald Isle event, WCDDA President's Reception and our WCDDA Winter meeting at the CAMLS center in Tampa and it's easy to see how the month flew by. We all owe a debt of gratitude to the great team we have at the WCDDA office led by Lissette Zuknick with Kelsey Bulnes and Cherri Rantz. They do such a magnificent job and it is all behind the scenes. I hope you get a chance to thank them because they are one of the reasons the West Coast is the Best Coast.

We had a wonderful President's Reception at the Armature Works in Tampa. It was a new venue and it was very well received with a good turnout. Awards were presented to some deserving individuals; The *Daniel Bertoch Leadership Award* was presented to Dr. Jessica Stilley of Tampa Bay. Her involvement and commitment at all levels of organized dentistry has made our association stronger and better. The *Kintsugi Award* for service and volunteering was presented to Dr. Sam Desai of Ft Myers. He was instrumental in the success of the Fort Myers Mission of Mercy event in 2018. He and his family have volunteered at each Florida Mission of Mercy event. He chaired the financial committee that was responsible for collecting all the donations to make the event happen. He and his team did such a magnificent job that we even had funds left over to apply towards the next event. We thanked him for his inspiration to restore lives by "putting the broken pieces back together". The *Distinguished Service Award* was given to an extremely deserving person, Dr. Paul Miller of New Port Richey. Dr. Miller has been actively serving in leadership since 1989 and continues currently. He has filled too many roles to even begin to list, but his commitment and contributions are significant. I want to thank and congratulate all the award winners!

The WCDDA team did their usual great job with our winter meeting. It was a big success and enjoyed by all. A big thank you goes to the Program Committee, chaired by Dr. Robin Nguyen. They had great speakers and never fail to deliver great CE.

More recently, we enjoyed a fantastic President's trip to New Orleans for Mardi Gras! A great time was had by all and we hope to see you for the next president's trip on the whiskey trail in Kentucky!

Enjoy life and remember "we are here for a good time, not a long time!" So, enjoy the time you are given! We hope you can make it to the Florida Dental Convention in Orlando and the Summer Meeting at The Ritz-Carlton, Naples Beach Resort. 🍷

Sincerely,
Oscar Menendez, DDS
President

INSIDE THIS ISSUE

2019 Annual Meeting and President's Trip	1-2
Optimize Your Practice in 2019	3
Membership Importance	4
New Members/Milestones	6-7
Mark Your Calendar	8
Association Business	8
Clinical Article	11
Tip of the Tongue	17

2019 Annual Meeting Memories

To view more meeting photos, visit <http://wccdaphotoalbums.shutterfly.com/>.



Exhibit hall frenzy!



Dr. George Kostokis, hoping for the winning ticket.




New Dentist lounge attendees. (l-r) **Dr. Deborah Lowry**, **Dr. Clay McEntire**, and **Dr. Lisa Brooks**.



President, **Dr. Oscar Menendez** is pictured with the 2019 award recipients. (L) **Dr. Paul Miller**, Distinguished Service Award, **Dr. Sam Desai**, The Kintsugi Award and (r) **Dr. Jessica Stilley**, the Dan Bertoch Leadership Award.



Past President huddle!



HCC Dental Assisting student presenting her poster.

Save The Date...

WCDDA's 98th Annual Meeting

Center for Advanced Learning and Simulation (CAMLS), Tampa
February 7, 2020

Currently Featuring:
 Eva Grayzel and
 Dr. Michael Kahn,
 speaking on
Oral Cancer
 Amy Kirsch, presenting
Practice Management.



2019 President's Trip to NOLA Mardi Gras



Dental friends and family enjoying Mardi Gras weekend. Join us next year on the Kentucky Bourbon Trail!

Optimize Your Practice in 2019

Code for What You Do and Do What You Code For!

2019 Optimize Your Practice: Understanding the CDT Code, Dental Benefits, Claim Processing, Contracts and More, Christopher Bulnes, DMD

This course will analyze several factors that influence a dental benefit plan's reimbursement for dental services you provide. Topics to be covered include benefit plan limitations and exclusions; participating provider contracts; effective appeal of denied claims; and proper, accurate and consistent Current Dental Terminology (CDT) coding on patient records and claims. How to use guides on recent CDT Code additions, such as the D4346 scaling code, will also be discussed.

Learning Objectives:

- ✓ Recognize how dental plan provisions affect reimbursement for services
- ✓ Implement ADA coding tools for accurate and error-free claim submissions
- ✓ Identify payer CDT Code misuse to appeal adjudication decisions

Dr. Bulnes is a general dentist in Tampa, FL. He earned his Doctorate of Dental Medicine degree from Southern Illinois University School of Dental Medicine, Alton, IL. He is also the Chair and a member of the ADA Council on Dental Benefit Programs. Dr. Bulnes also serves as the Chair of the Code Maintenance Committee.

\$50.00 Members/Team Members
\$75.00 Non-Members/Team Members

Follow the link for more information and to register,
<http://www.cvent.com/d/x6qqyc>



Christopher Bulnes, DMD

Optimize Your Practice and Register You and Your Team Today!

April 26, 2019
CAMLS, Tampa

CDT is a reference manual published annually by ADA, and it contains the Code on Dental Procedures and Nomenclature (CDT Code). The CDT Code is a set of procedural codes for oral health and adjunctive services that are provided in dentistry.



Affiliate Corner

Hillsborough County Dental Association recently hosted their annual Diva's in Dentistry event held at the Oxford Exchange in Tampa. FDA's Chief Legislative Officer, Joe Anne Hart was in attendance to provide important legislative updates to the Dental Divas.



Member Tools and Resources

ADA Find a Dentist Feature: The online tool, mouthhealthy.org promotes your practice by allowing you to keep your profile up to date and making it easy for potential patients to locate your practice.

FDA Services: Provides a wide range of insurance at affordable rates. Individual/Group Health, Professional Liability, Term Life, Workers Compensation, Disability, Malpractice, Auto and Pension plans are available. Contact Rick D'Angelo at (813) 475-6948 or rick.dangelo@fdaservices.com.

Crown Savings: FDA Services has researched and vetted business solutions so members can take advantage of exclusive deals and discounts offered through the Crown Savings program. Members who participate will save time, money and hassle, putting the focus back on patient care. Visit fdaservices.com/crownsavings.

ADA Credentialing: Spend more time with patients and less time on cumbersome, redundant paperwork. Think like a dentist and run your office like an entrepreneur with ADA's Credentialing Service. Visit ada.org/credentialing.

ADA/FDA/WCDDA Websites: Information right at your fingertips, visit ada.org, floridadental.org and wcdental.org to access important information on laws, rules, and continuing education and employment opportunities.. Visit ADA's New Dentist Blog, newdentistblog.ada.org and FDA's Beyond the Bite Blog, floridadental.org/members/fda-blog.

CE Programs/Annual Meetings/Affiliate Meetings: Each association hosts annual meetings and monthly meetings that provide high quality continuing education to members and their staff at a significantly reduced rate. WCDDA's Annual Winter and Summer Meetings, WCDDA Affiliate Meetings, Florida Dental Convention (FDC) and the ADA's Annual Session.

Free Florida and HIPAA Compliance Forms: Free HIPAA forms are available to all members. Visit floridadental.org/members/member-resource

Free Online CE: Members receive up to 30 hours of FREE online CE courses at floridadental.org.

CE Broker Tracking: Continuing education attendance records are uploaded into CEbroker.com for each member who attends a meeting at the FDA, WCDDA and affiliate levels.

FOR MORE INFORMATION ABOUT MEMBERSHIP AND HOW TO JOIN, CALL (800) 260-5277 OR VISIT, floridadental.org/member-center/benefits OR wcdental.org.

FDAPAC AND ADPAC

Dentistry's state and federal political action committees ensure the association has a place at the table when lawmakers are debating legislation that affects dentistry. The FDA Political Action Committee (FDAPAC) Board of Directors and American Dental Political Action Committee (ADPAC) work hard to identify and support dental-friendly candidates. To stay informed, visit ada.org/advocacy.aspx and floridadental.org.

FLUORIDATION

The FDA is a leading advocate for fluoridation and many times must act fast when the removal of fluoride is threatened. As Florida's advocate for oral health, the FDA helps educate community leaders on the benefits of fluoridation and provides expert testimony before commission meetings, when needed. The FDA works with state agencies and the ADA to promote fluoridation. To increase education efforts and promote fluoridation, the FDA created a fluoridation specific website, floridafluoridation.org

MANAGED-CARE HANDBOOK

You Want Me to Sign What? A Florida Dentist's Handbook on Managed-care Contracts is a comprehensive reference including information on reimbursement, risk, negotiating, and rights and duties of both parties. Contact the WCDDA office to obtain your copy, (813) 654-2500.

ADA CENTER FOR PROFESSIONAL SUCCESS

This interactive web resource offers members relevant and effective solutions you can use every day: managing your career, expanding your knowledge and balancing your life. Visit success.ada.org/en/.

- Marketing Strategies for Your Practice - <https://bit.ly/2BT6HOc>
- Running a successful dental practice presents new challenges every day. The ADA's Guidelines for Practice Success™ (GPS™) delivers the resources you need to achieve your practice goals. <https://success.ada.org/en/practice-management/guidelines-for-practice-success>
- Survey of Dental Fees, <https://success.ada.org/en/practice-management/finances/survey-of-dental-fees>

FDA CAREER CENTER gives dentists and dental employers a better way to find each other and make that perfect match. Visit, floridadental.org/member-center/fda-career-center.

THIRD-PARTY PAYER CONCERNS:

Working closely with the various insurance plans, Medicaid managed-care plans, the Agency for Health Care Administration (AHCA), Department of Health, Board of Dentistry and other state and federal agencies, the FDA Director of Thirdparty Payer and Professional Affairs addresses issues relating to third-party payers such as: * Insurance and Medicaid managed-care plan reimbursement * Contracting with commercial insurance and Medicaid managed-care plans *Filing complaints with the Office of Insurance Regulation and/or the Agency for Health Care Administration *General third-party payer questions *Regulatory issues with the Board of Dentistry. For additional info, contact Casey Stoutamire, Director of Third Party Payer & Professional Affairs 800.877.9922 • cstoutamire@floridadental.org.

YOU OFTEN CAN AVOID COSTLY LEGAL FEES and malpractice suits by using this free service available only to members. Peer Review doesn't always have to be started by a disgruntled patient. A frustrated dentist who feels that everything has been done to satisfy the patient, with no success, also can recommend Peer Review. This is a service provided by colleagues to other members to help mediate problems, and most of the time avoid costly and emotionally draining litigation or Board of Dentistry complaints.

View ADA's 2018 Highlights YouTube video here, <https://www.youtube.com/watch?v=D1jA8x8Q6kl&feature=youtu.be>

AFTCO

TRANSITION CONSULTANTS
Since 1968

50 years strong

1968-2018

When success matters ...you can depend on AFTCO, the oldest and largest dental practice transition consulting firm in the United States. AFTCO offers more than 150 practice transition programs custom designed to provide every dentist with a more secure future and a well-earned Quality of Life. Let our 50 years of experience provide you with the direction you need to make the most of your future.

www.AFTCO.net | 800.232.3826



RADIOGRAPHY TRAINING ONLINE. CONVENIENT. SELF-PACED. AFFORDABLE.

The new Florida Dental Association (FDA) Online Radiography Training Program is the most convenient and economical way to ensure your assistants receive the radiography training required by Florida law. No need for travel or time away from work. Your dental assistants train online, under your supervision, at their own pace.

It's affordably priced, too — just \$285 per student for FDA members!
To find out more or to get started, visit MyDentalRadiography.com/fda.



Florida's Action for Dental Health

Too many Floridians face challenges in accessing routine, preventive dental care. It's time to get to the root of improving oral health in Florida.

Key FDA initiatives

Florida Donated
Dental Services

Safety Net
Programs

Community Dental
Health Coordinator

Student Loan
Repayment

dentalhealthfl.org

The Florida Dental Association (FDA) wants you to be as informed as possible about FDA policy issues during the Florida Legislative Session. Visit dentalhealthfl.org to learn about our oral health initiative, *Florida's Action for Dental Health*, and the many components that make this a comprehensive solution for addressing access to dental care.

New Members

The following dentists have recently joined or reinstated membership to the WCDDA, FDA and ADA! Congratulations and welcome!

Dr. Scott Antonio, Pensacola
Dr. Dillon Bale, Tampa
Dr. Kristina Beg, Clearwater
Dr. Jason Blundell, Palm Harbor
Dr. Gregory Brandau, Placida
Dr. Lisa Brooks, Land O Lakes
Dr. Gary Burkholder, Fort Myers
Dr. Isabel Castillo, Bradenton
Dr. Christopher Cetta, Clearwater
Dr. Norman Clement, Tampa
Dr. Amanda Colonneaux, Riverview
Dr. Elio D'Amico, Naples
Dr. Marc Dadkhah, Naples
Dr. Jennifer Depew, Lakeland
Dr. Teresa Dolan, Longboat Key
Dr. Francisco Gari, Tampa

Dr. Martin Giacobbi, Tampa
Dr. Lacy Gilbert, Bonita Springs
Dr. Nina Guba, Winter Haven
Dr. Shadan Hafsa, Brandon
Dr. Dylan Hagerty, Ruskin
Dr. Sherief Hussein, Tampa
Dr. Thomas Johnson, Largo
Dr. Robert Krachenfels, Tampa
Dr. Christina LePochat, Zephyrhills
Dr. Lauren Maass, Odessa
Dr. Susana Martinez, Bradenton
Dr. Andrew Mikhail, Wesley Chapel
Dr. Zulima Munoz, Naples
Dr. Aderonke Ogunbameru, Tampa
Dr. Edwin Parks, Fort Myers Beach
Dr. Ulysses Patalinghug, Fort Myers

Dr. Annelise Perez, Fort Myers
Dr. Sujata Prasad, Naples
Dr. Ovy Quintanal, Bradenton
Dr. James Renner, Dunedin
Dr. Youssef Riad, Oldsmar
Dr. Alejandra Rivera, Lakeland
Dr. Rodrigo Romano, South Miami
Dr. Gregory Ross, Clearwater
Dr. Earl Santos, Clearwater
Dr. Scott Scheps, Lakeland
Dr. Antoinette Severino, Nokomis
Dr. David Smith, Englewood
Dr. Erika Tugendhat, Miami
Dr. Michael Valancius, Tampa
Dr. Jacqueline Vineyard, Tierra Verde



Substitute Dentistry for Florida

Quality Care for your patients while you are away

Would you like to Get Away?
Sudden Illness or Disability? Maternity Leave?

Don't close your office!

Retain your patients and dental team.

Walter F. Zoller, D.M.D.
Space Coast Dental Locum Tenens

'Fill-in' Services Taken Seriously
This is our business - **NOT a hobby!**
Easy Access throughout the sunshine state.

Call at your time of need - 321-223-6829

FLSubDentist@gmail.com

www.FLSubDentist.com

In Memoriam

We are deeply saddened by the death of our colleagues.

Richard Eugene Adams, DDS of Hernando – December 12, 2018 *past president of the WCDDA*

Mark Joseph Brunswick, DDS of Venice – February 28, 2016

Harold Eldon Grundset, DDS of Trinity - August 1, 2015

Ronald Higel, DDS of Venice – November 5, 2017

John Thomas McGaughey, DDS – January 1, 2018

Dale R. Pellot, DDS of Fort Myers - July 6, 2018

Gustave J. Perdigon, DDS of Tampa - December 24, 2018 *past president of the WCDDA*

Stephen Michael Reynolds, DDS of Tampa - February 28, 2018

John H. Ross, DDS of St. Petersburg – October 30, 2018

Richard Tomlin, DMD of Seminole – November 12, 2018

Robert Edward Westman, DDS of Naples - March 1, 2016

A contribution has been made to the WCDDA Fund in their memory. If you would like to make a contribution, please make your check payable to the Florida Dental Health Foundation, indicate WCDDA Fund in the memo and mail to: Florida Dental Association, Attn: Foundation, 1111 East Tennessee Street. Tallahassee, Florida, 32308-6914.

Members Showing Commitment

Congratulations to the following members for their continued commitment! The year 2019 marks their major milestone in supporting organized dentistry.

25 Year

Dr. Ziad Abou-Assi, Tampa
Dr. Pedro Belaunzaran, Tampa
Dr. Brent Beyer, Venice
Dr. Steven Ciaravino, Haines City
Dr. Augusto Conte, Brandon
Dr. Adam Diasti, Tampa
Dr. Teresa Dolan, Longboat Key
Dr. George Dumouchel, Naples
Dr. Gianni Franceschi, trinity
Dr. Edgard Francisco, Tampa
Dr. Gustavo Fuentes Perez, Fort Myers
Dr. J. Mauricio Giraldo, Brandon

Dr. Lauren Governale, Naples
Dr. Michelle Halcomb, Brandon
Dr. Timothy Higgins, Punta Gorda
Dr. Mike Insoft, Saint Petersburg
Dr. Susan King, Tampa
Dr. Steven Knepper, Estero
Dr. Theresa Kohlberg, Saint Petersburg
Dr. Steven Leikin, Naples
Dr. Dennis Logue, Palm Harbor
Dr. Deborah Lux, Punta Gorda
Dr. Caitilin Martini, Tampa
Dr. Todd McCabe, Bradenton

Dr. Christopher McCash, Naples
Dr. Chi Nguyen, Sun City Center
Dr. Michael Orrantia, Brandon
Dr. Theodore Peters, Tampa
Dr. Kathryn Ringland, Fort Myers
Dr. Michael Rowe, Saint Petersburg
Dr. Larry Saylor, Brandon
Dr. John Schreier, Brandon
Dr. Frank Sierra, Tampa
Dr. Frank Vascimini, Homosassa
Dr. Sheryl Watkins, Labelle
Dr. Lee Welky, Estero

35 Year

Dr. Richard Demarsh, Tampa
Dr. Linda Laabs, Sarasota
Dr. Mark Mellman, Tampa
Dr. Howell Morrison, Tampa
Dr. Michael Adams, Clearwater
Dr. Pamela Adams, Clearwater
Dr. David Brown, Largo
Dr. Scott Bryington, Zephyrhills
Dr. Tom Crawford, Saint Petersburg
Dr. John Eifert, Clearwater

Dr. Joseph Ellis, French Lick
Dr. Daniel Endrizal, Fort Myers
Dr. Ralph Fortson, Tampa
Dr. Barbara Fueredi, Naples
Dr. David Gordon, Hernando
Dr. Timothy Herring, Sarasota
Dr. Ronald James, Lakeland
Dr. Joseph Karkut, Naples
Dr. Donald Lackey, Venice
Dr. Rudolph Liddell, Brandon

Dr. Lawrence Lieberman, Palm Harbor
Dr. Frank Mazzeo, Naples
Dr. Carole Medvesky, Clearwater
Dr. Paul Mevoli, Treasure Island
Dr. Frederick Muenchinger, Tampa
Dr. Shoukry Soliman, Clearwater
Dr. Dennis Sweeney, Fort Myers
Dr. Harold Welch, Seffner
Dr. G Wilhelm, Jupiter
Dr. Hugh Wunderlich, Palm Harbor

50 Year

Dr. Gary Baines, Apollo Beach
Dr. Samuel Caranante, Tampa
Dr. John Davis, Hernando
Dr. Daniel De Russy, South Pasadena
Dr. Thomas Devine, Blairsville
Dr. Dennis Fernandez, Seminole

Dr. Donald Lintzenich, Evans
Dr. C Marshall, Port Charlotte
Dr. Joseph Moschella, Largo
Dr. Kevin Pasley, Fort Myers
Dr. Jon Rauch, Naples
Dr. William Robinson, Tampa

Dr. James Vandenberghe, Palm Bch. Gardens
Dr. R. Geoffrey Weihe, Tampa
Dr. David Winkler, Sarasota
Dr. Carl Zielonka, Tampa

60 Year

Dr. Robert Beem, Dunedin
Dr. Joe Bratton, Odessa
Dr. Thaddeus Brzozowski, Lakeland
Dr. Antonio Castro, Lutz
Dr. Peter Pizaris, Fort Myers
Dr. Kenneth Roberts, Auburndale
Dr. Jack Shaffer, Lutz
Dr. Donald Wadsworth, Tampa
Dr. Robert Willis, Sarasota
Dr. Danilo Zucchelli, Clermont

Life

Dr. Nicholas Dundee, Cape Coral
Dr. John Hyatt, Fort Myers
Dr. James Minici, New Port Richey
Dr. Matthew Nieber, Saint Petersburg
Dr. David Trettenero, Fort Myers
Dr. Rodney Ackley, Spring Hill
Dr. Thomas Averitt, Sarasota
Dr. Christopher Bonham, Largo
Dr. Thomas Brick, Naples
Dr. Barbara Coy, Sarasota
Dr. Robert Crim, Irvine

Dr. Daniel Dietz, Bonita Springs
Dr. Robert Ettleman, Tampa
Dr. Michael Grant, Saint Petersburg
Dr. Ron Hill, Belleair
Dr. Vincent Lovetto, Naples
Dr. Kathryn McClintock, Madeira Beach
Dr. James Mitchell, Fort Myers
Dr. James Morrish, Bradenton
Dr. Richard Rasmussen, Tampa
Dr. Sanford Schwartz, Brandon
Dr. Bruce Waterman, Lakewood Ranch
Dr. Dewitt Wilkerson, Saint Petersburg



Association Business - Official Calls

Official Calls

There will be a caucus of the West Coast District Dental Association's Delegation on Tuesday, June 18, 2019 at 6:00 p.m. via conference call. There will be twelve sites throughout the West Coast district.



Dr. Rita Hurst

The West Coast District Dental Association will hold a breakfast caucus in conjunction with the Florida Dental Association's House of Delegates meeting Saturday, June 29, 2019 at 7:00 a.m. at the Gaylord Palms, Orlando

The WCDDA Executive Cabinet voted to eliminate the position of the Vice President from the line officer ladder. The next election for WCDDA will be held in 2020.

Dr. Rita Hurst
WCDDA Secretary

*You're Invited to attend
WCDDA's
Officer Installation
Saturday, July 27th
5:00 p.m.
The Ritz-Carlton, Naples Beach Resort*

*Event held in conjunction with the
West Coast District Dental Association's
2019 Summer Meeting.*

WCDDA Team

WCDDA's Executive Assistant, Cherri Rantz is relocating to Tennessee. Cherri has contributed to the success of the association and the central office for the past 2 years. The WCDDA officers and staff will miss her dearly but we are very happy for her and her family's new venture.

The WCDDA would like to welcome Kim Dresser to be a part of the team. Kim brings years of association experience including 6 years with the Maryland State Dental Association as their director of membership. She also served as the executive director for one of their local dental components. Her experience has ranged in industries including physician leadership training, natural products, home building and wind energy to name a few. Member engagement is what Kim enjoys and looks forward to focusing on in her new position. Kim lives in Valrico with her husband and 3 children.



Kim Dresser

Mark Your Calendar 2019-2020

WCDDA Executive Cabinet Meeting, Brandon May 17, 2019

WCDDA Delegation Caucus, Various Sites June 18, 2019

FDC, Gaylord Palms, Orlando June 27-29, 2019

FDA House of Delegates, Gaylord Palms, Orlando . . June 28-29, 2019

WCDDA Summer Meeting, The Ritz-Carlton, Naples. July 26-28, 2019

America's Dental Meeting, San Francisco September 5-9, 2019

WCDDA President's Reception, Tampa February 6, 2020

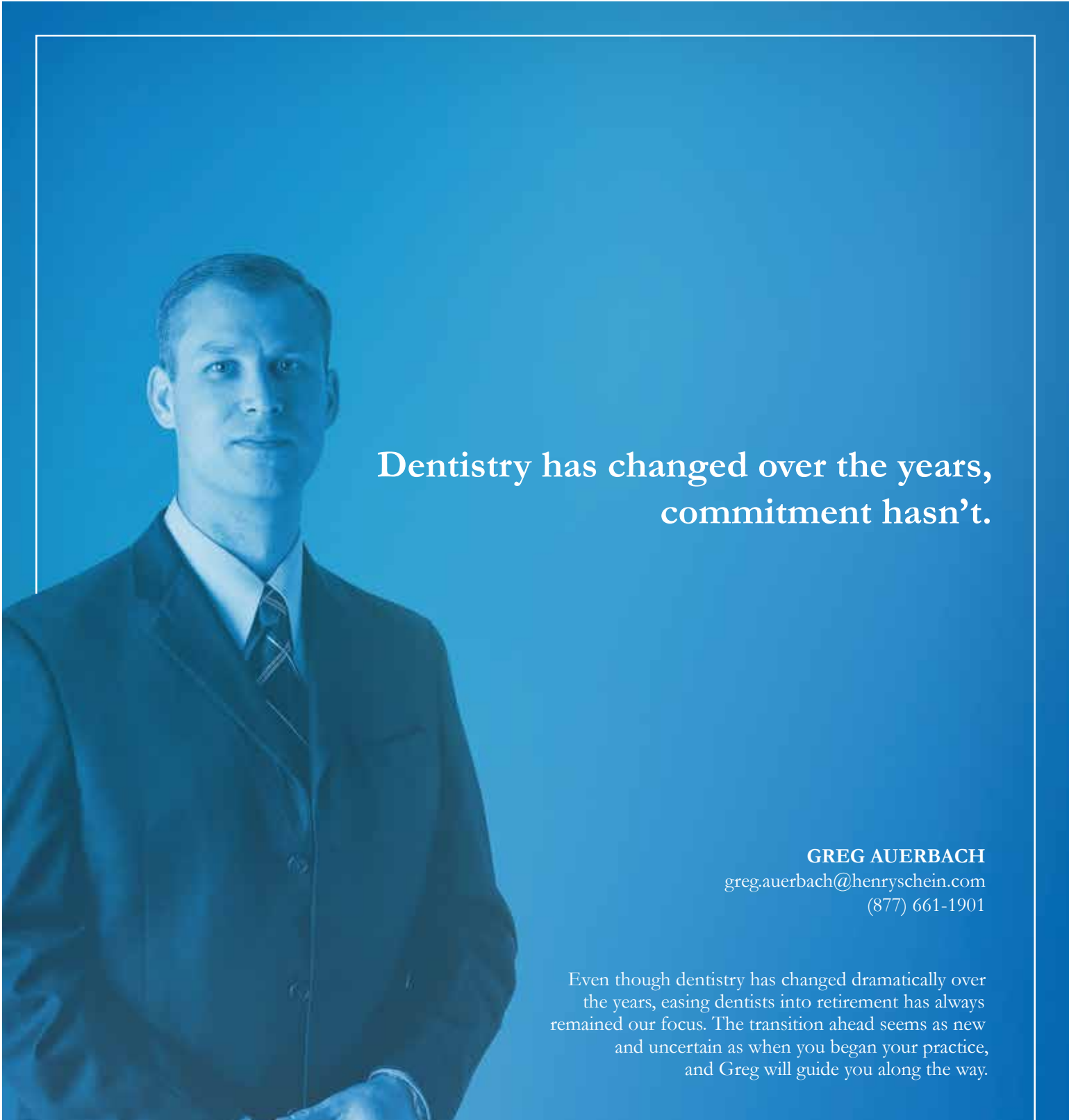WCDDA Annual Meeting, CAMLS, Tampa . . . February 7, 2020

Florida's Mission of Mercy Event, Jacksonville . . . April 24-25, 2020

FDA House of Delegates, Gaylord Palms, Orlando . June 12-13, 2020

WCDDA Summer Meeting, The Ritz-Carlton, Naples. . . Aug 7-9, 2020

America's Dental Meeting, Orlando October 15-19, 2020



Dentistry has changed over the years, commitment hasn't.

GREG AUERBACH

greg.auerbach@henryschein.com

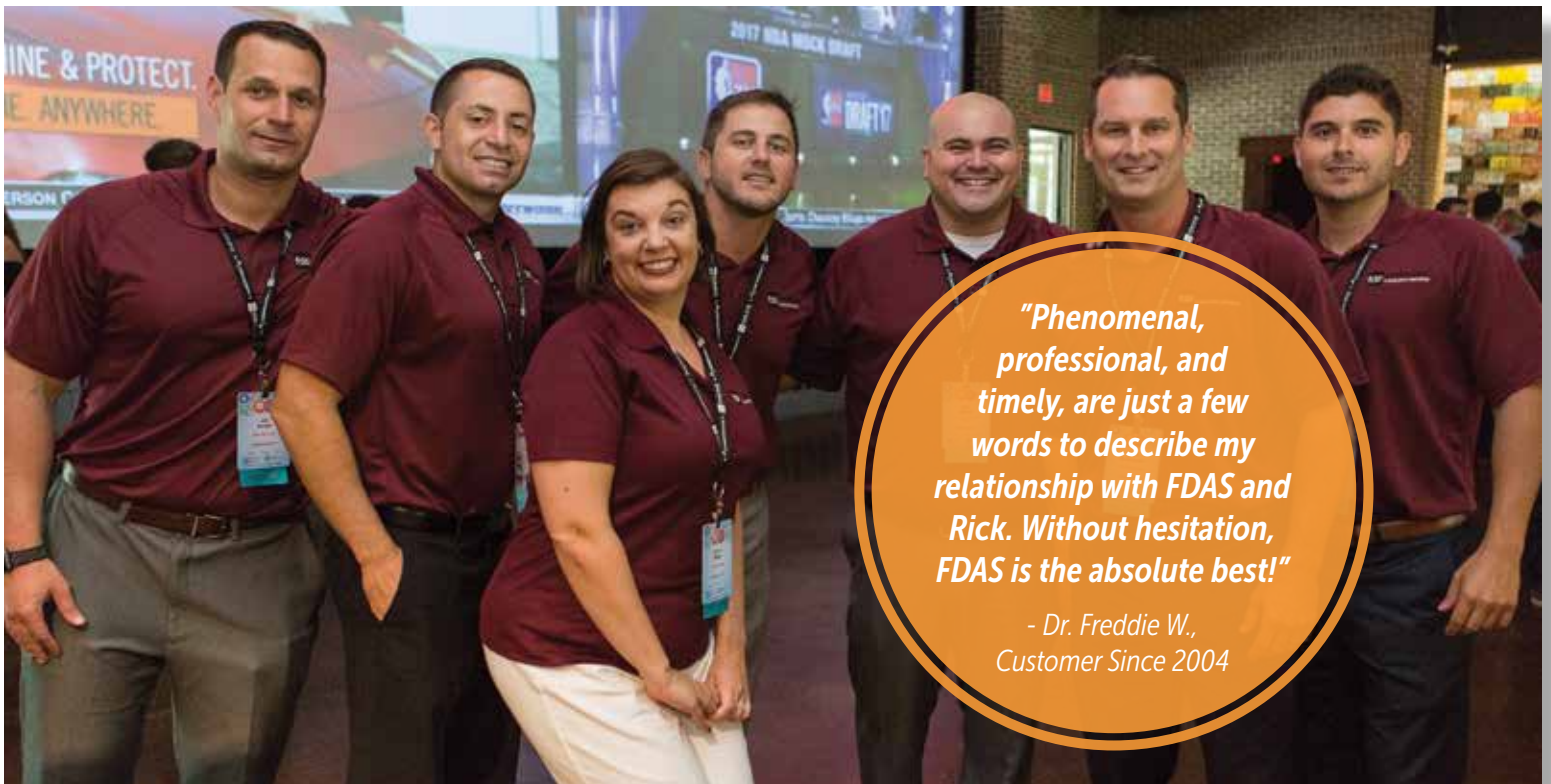(877) 661-1901

Even though dentistry has changed dramatically over the years, easing dentists into retirement has always remained our focus. The transition ahead seems as new and uncertain as when you began your practice, and Greg will guide you along the way.

 **HENRY SCHEIN**[®]
PROFESSIONAL PRACTICE TRANSITIONS

HenryScheinPPTFlorida.com
HenryScheinPPT.com

■ PRACTICE SALES ■ VALUATIONS
■ TRANSITION CONSULTING/
PLANNING ■ ASSOCIATESHIPS



"Phenomenal, professional, and timely, are just a few words to describe my relationship with FDAS and Rick. Without hesitation, FDAS is the absolute best!"

*- Dr. Freddie W,
Customer Since 2004*



COUNT ON YOUR FDAS AGENT!

RICK D'ANGELO - WEST COAST

YOU CAN TRUST YOUR FDAS INSURANCE AGENT LIKE A MEMBER OF YOUR DENTAL TEAM...

We have the knowledge, experience and insurance providers to assure that you have the coverage you need to practice with security and peace of mind.

INSURANCE PRODUCTS:

- » Professional Liability
- » Office Package
- » Disability Income
- » Office Overhead
- » Workers Comp
- » Group Health
- » Individual Health
- » Life Insurance
- » Long-Term Care
- » Annuities
- » Auto & Boat
- » More...



CONTACT RICK

P: 813.475.6948 | F: 813.475.6959 | E: rick.dangelo@fdaservices.com

www.fdaservices.com/insurance-programs | Follow us on



MANAGEMENT OF ODONTOGENIC INFECTIONS

Originally printed in the *Arkansas Dentistry*:
Spring 2018 issue. Reprinted with permission
from the Arkansas Dental Association.

CHAD S. ADAMS, D.D.S.

*University of Arkansas For Medical Sciences
General Practice Residency*

One of the hallmarks of being a healthcare provider in a hospital system is treating patients who have entered into a more advanced stage of the disease process. In the case of dentistry, this usually implies a severe odontogenic infection. Patients are overwhelmingly unaware of how serious a “cavity” can become, both locally and systemically. As a practitioner, part of our commission is to treat these individuals with the best care that can be provided. Ultimately, prevention and diligence on the part of the patient and the provider will largely preclude a severe odontogenic infection from arising; however, when a case inevitably presents, it is our responsibility to be equipped with the skills and the knowledge to produce a successful outcome. The intention of this paper is to educate and to offer guidance in the treatment planning options for patients with severe odontogenic infections.

Before discussing treatment options for patients presenting with odontogenic infections, it is important to first understand the source of infection as well as to fully understand the disease process. Odontogenic infections are bacterial-mediated. They occur when bacteria gain entrance into the periapical space of a tooth by way of the pulp, pericoronal tissue, or the periodontium. In terms of frequency, author Flynn, et al., explains that “the most frequent dental disease leading

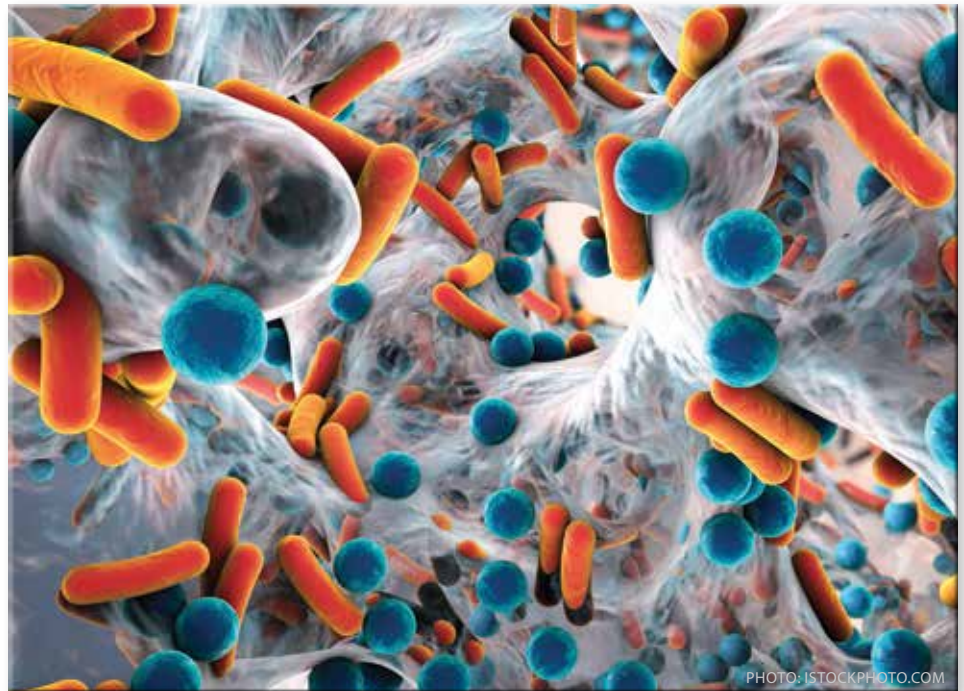


PHOTO: ISTOCKPHOTO.COM

The intention of this paper is to educate and to offer guidance in the treatment planning options for patients with severe odontogenic infections.

to severe odontogenic infection was caries (65%), followed by pericoronitis (22%), and periodontal disease (22%) (2006). The severity of the infection is multifactorial, but is largely dependent upon the microflora present. Though it has been shown that roughly 700 different species

of bacteria can be present at any given moment in the oral cavity, it is the specific compilation as well as location, which can permit such an infection to propagate (Mougeot, et al., 2015). Odontogenic infections are polymicrobial in nature and

are predominately anaerobic gram-positive cocci and gram-negative rods. It is the virulence factors of these bacterial species that allow them to be so effective.

Stefanopoulos and Kolokotronis state that, "pathogenicity [of bacterial] include aerotolerance, a variety of bacterial enzymes, toxins, and metabolites detrimental to the host, possession of a capsule with antiphagocytic and abscessogenic properties, and bacterial synergism" (2004). Because odontogenic infections are mixed infections, the bacteria are able

as a virulence factor by stimulating the production of inflammatory cytokines" (Stefanopoulos & Kolokotronis, 2004). Endotoxin, hydrogen sulfide, and other proteolytic enzymes are inherently cytotoxic. This accounts for tissue degradation resulting in the continuing spread of the infection. The addition of the beta-lactamases family of enzymes to some of these bacterial species increases their pathogenicity by inactivating two of the most commonly used antibiotic classes of drugs.

Without removing the source of infection by way of endodontic therapy or exodontic therapy, this process can repeat over and over again in a patient with an odontogenic infection.

to behave synergistically; this allows bacteria to survive alongside one another when impossible on their own. An example of the effectiveness of this synergism can be witnessed in the presence of oxygen. As stated, the major bacteria involved in these infections are typically anaerobic; this implies that in the presence of oxygen they are unable to survive. In a mixed infection, there are facultative anaerobes present that decrease the oxygen tension in the living tissue, which can allow for obligate anaerobes to survive. On a related note, moderate anaerobes are able to combat the oxygen presence by an enzyme called superoxide dismutase.

An assortment of enzymes and toxins that these bacteria possess or metabolically produce further accounts for the severity of these infections. The capsular polysaccharide found surrounding some bacteria gives them antiphagocytic qualities as well as the ability to stimulate inflammation. "Lipid polysaccharide plays an important role in the initiation and magnification of abscess formation acting

This brief introduction into the microflora of odontogenic infections has shown how these bacteria are able to be so effective in their pathogenicity. Now it is important to understand the staging of the infection and what practitioners should look for when a patient presents with symptoms of infection.

The inoculation of invading bacterial species into the tissue is the first stage of the infection process. There is an early inflammatory period at this time, due to the presence of the invading bacterial; this inflammation will ultimately cause edema. Clinically, this is significant because clinicians are able to objectively see signs of the infection. Two to five days into the infection, the edema will have progressed and cellulitis develops. The softer swelling of the initial stage will begin hardening. This infected area will be hot to the touch, quite tender, and will rapidly enlarge. From this stage to the next stage the cellulitis begins transitioning into an abscess formation. Four to seven days into the infection, the hard-

ness will soften, and the underlying tissue will form a necrotic mass of granulation tissue, sequestered bacteria, and immunologically-active cells. Abscess formation helps by walling off the infection allowing the immune system of the host to effectively kill the invading bacteria and to stop further spread (Flynn, 2000).

Without removing the source of infection by way of endodontic therapy or exodontic therapy, this process can repeat over and over again in a patient with an odontogenic infection. At this point, the patient will ultimately have a chronically abscessed tooth. The necrotic tissue in the periapical area will eventually penetrate through the cortical plate of the alveolar bone in the path of least resistance. "Changes in the cortical plates were observed more frequently in the labial and buccal side than in the palatal side," according to Obayashi, et al., when discussing maxillary abscesses (2004). Once through the bone and soft tissue, a fistula with draining exudate is the common presentation that practitioners are all too familiar with. It is quite common for patients to be unaware of the severity of complications that an odontogenic infection can produce. They will often admit to having a draining abscess present over the course of months to even years. In many cases, no life-threatening infection will occur.

Now that staging of a typical odontogenic infection has been fully appreciated, it is imperative to understand how an odontogenic infection becomes severe. The classic example is that of Ludwig's angina. "Ludwig's angina is a bilateral infection of the submandibular space that consists of two compartments in the floor of the mouth, the sublingual space and the sub mylohyoid space" (Chow, 2015). The hallmark of this disease process is airway obstruction. This occurs by the bilateral spread of the cellulitis. Mandibular second and third molars are most likely to be the source of infection resulting in Ludwig's angina. This is due to the location of the roots of these teeth in relation to the fascial planes necessary

to be crossed, notably beyond the attachments of the mylohyoid muscles, in order to infect the submandibular space. It should be noted “fascial layers prevent inflammatory spread, once the infection spreads into the muscle beyond the fascia, the muscle itself can transfer inflammation to the adjacent tissues” (Obayashi, et al., 2004).

The symmetrical presentation of the swelling in Ludwig’s angina is due to the aforementioned spread of infection. If the infection were instead spread through lymphatic involvement, one would note that the swelling and infection would be unilateral. This is an important finding that would rule out a diagnosis of Ludwig’s (Chow, 2015).

An established infection in the submandibular space will cause the tongue to swell and be pushed in a posterior direction towards the hypopharynx and superiorly against the palate. These factors, along with infection spread to the retropharyngeal and parapharyngeal spaces,

of choice” at this time (Chow, 2015). In many cases magnetic resonance imaging can offer a superior image to that of a CT in regards to the initial evaluation of a patient with deep space infections; however, the authors Bali, et al., explain that this is not a practical option for many emergency cases (2015).

A severe odontogenic infection does not only present itself in the form of Ludwig’s angina, the spread of infection can follow many fascial layers. According to Jose, et al., “maxillofacial infections are known to spread intracranially by direct extension along the fascial planes or by hematogenous route into the cavernous sinus” (2014).

This route of infection is typically seen when the infraorbital space has become involved. There are angular veins that run through this space, and when a septic thrombophlebitis enters these veins it can then ascend into the cavernous sinus through valveless veins. Once present in the cavernous sinus, a thickening of the

fact, 60%-70% of cases of descending necrotizing mediastinitis have been implicated in resulting from unresolved odontogenic infections (Sakamoto, et al., 2000).

Another potential danger of odontogenic infections lies in the bacteria’s ability to gain entrance to the blood stream. This bacteremia can produce numerous distant site infections. Infective endocarditis is one such infection.

Infective endocarditis (IE) is inflammation that occurs in the endocardium of the heart. Artificial heart valves are more commonly associated with cases of IE than native heart valves. The species of bacteria that are present in the oral cavity are associated with the same infecting bacterial species as with IE. Though extracting infected teeth can help remove a source of the bacteria associated with IE, it has been shown that extractions in and of themselves can cause bacteremias, which have the potentiality to cause IE.

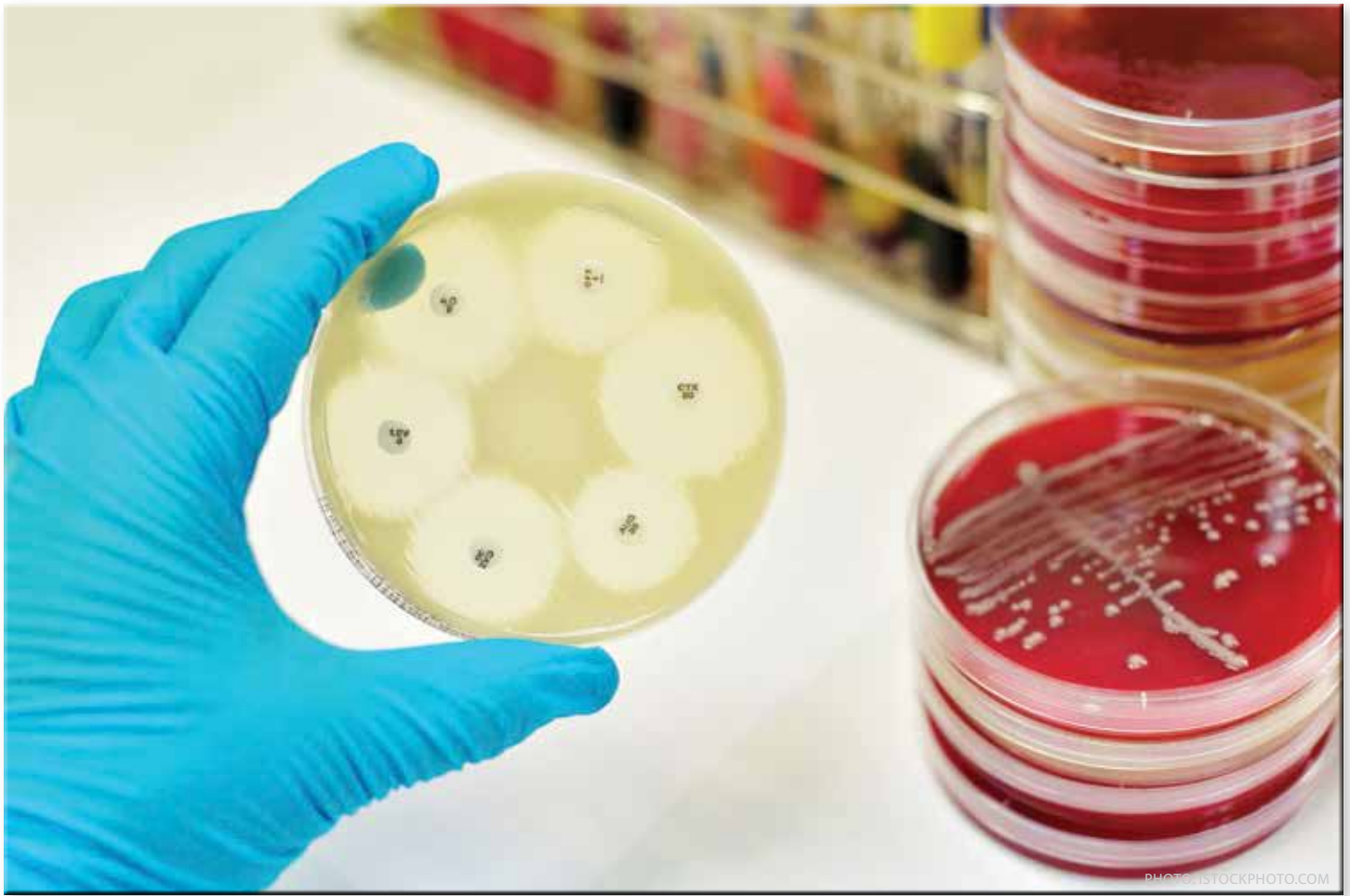This discovery has prompted many to prophylactically medicate high-risk patients with antibiotics prior to extraction of diseased or even virgin teeth. Such conditions deemed high-risk include: artificial heart valves, orthopaedic joint prostheses, immunosuppressed patients, as well as patients with catheters or shunts for hemodialysis (Lockhart et al., 1999). The use of prophylactic antibiotics for the purpose of preventing distant site infections (DSI) has many opponents. Some argue that organisms that cause IE and other DSI can be found in the upper and lower digestive tract, skin, as well as the upper respiratory tract. These extraoral sites could also be the source of IE and DSI. Mougeot et al. explains “although [antibiotic prophylaxis] decreases the frequency of all oral bacterial species, both tooth brushing and single tooth extractions disrupt similar bacterial species in similar proportions” (2015). This finding suggests that, regardless of antibiotic prophylaxis, bacteremias are present in similar microbial-content as well as quantity following a common task such as brushing one’s teeth. Though the literature currently asserts that this bacteremia is

Though extracting infected teeth can help remove a source of the bacteria associated with IE, it has been shown that extractions in and of themselves can cause bacteremias, which have the potentiality to cause IE.

accounts for the airway occlusion. Airway obstruction can be slightly relieved by having patients assume the “sniffing position.” This position helps to straighten the upper airway allowing for a more patent airway (Flynn, 2000). It should be noted that due to the swelling of the tongue, occlusion of the airway, and palatal involvement the patient would have a difficult time communicating verbally. This can further complicate getting necessary information from the patient for proper treatment. For a definitive diagnosis of Ludwig’s angina, “a computed tomography scan is the imaging modality

meningeal walls can produce compression of cranial nerves III-VI resulting in signs of neuropathy.

Though Ludwig’s angina and cavernous sinus involvement are two of the more severe complications associated with odontogenic infections, many other head and neck spaces can become involved. The following other spaces can be involved: buccal, infraorbital, subperiosteal, vestibular, submental, masticatory, submasseteric, pterygomandibular, temporal, lateral pharyngeal, and retropharyngeal. There have been cases of mediastinitis resulting from odontogenic infections. In



caused on a daily basis through normal activities, it should be left to the discretion of the practitioner whether or not prophylactic antibiotics are prescribed. Consider the patient's systemic conditions, history with IE, as well as other extenuating circumstances when formulating a decision. Despite acting against the literature, the litigious society in which one lives makes this decision more difficult.

A clear understanding of the cause and the process of complications resulting from severe odontogenic infections has been provided. Understanding how to manage these patients surgically is the next phase.

As one would imagine, removal of the source of infection is the primary goal for treatment of odontogenic infections. This can take many forms. Less severe infections can be primarily treated by extraction of the infected tooth and curettage of the socket. Antibiotics can be a good supplement to primary treatment; however, this is not always necessary. In

more severe cases, "the establishment of gravity-dependent surgical drainage of deep space odontogenic infections is the primary treatment" (Flynn, 2000). By opening up the infected space, a significant portion of the microbial load will be removed allowing leukocytes to gain better access to the remaining infection. Not only is the infected space more accessible, but also by collapsing the avascular abscess cavity, blood is able to more effectively flow near and into the infected space increasing local leukocyte numbers.

Following incision and drainage, most surgical sites will stop producing exudate in two to three days. Complete resolution is often seen five to twelve days post-operatively. To further increase healing response time, patients are often placed on antibiotics as well as instructed to place moist heat on the infected tissue. This will trigger vasodilation in the associated area resulting in a more prompt resolution of the infection by a "rapid removal of tissue breakdown

products and a greater influx of defensive cells and antibodies" (Bahl et al., 2014).

As indicated in the previous passage, antibiotic therapy is typically used in conjunction with surgical drainage or removal of the offending tooth, but not as the sole treatment. The most accurate method for choosing an antibiotic class, assuming no drug allergies, is culturing for the purpose of determining antibiotic efficacy. Though, a more pragmatic choice would be to place the patient on an antibiotic class that is statistically likely to be efficacious against bacteria that are commonly the cause of odontogenic infections. At this time, "penicillin remains the drug of choice in the management of most odontogenic infections" (Bahl et al., 2014).

Due to an increase in penicillin-resistant bacteria, it has become common practice to additionally place the patient on clavulanic acid to counter the beta lactamase enzyme. In addition, many practitioners will add metronidazole to the antibiotic combination to aide in the reso-

As one would imagine, removal of the source of infection is the primary goal for treatment of odontogenic infections. This can take many forms.

lution of more serious anaerobic bacterial species. Regardless of the concoction of antibiotics that has been chosen, it is imperative to monitor the efficacy. If infection is not responding, one must culture and choose a more effective drug class. Tomas, et al. conclude that “clindamycin should be considered as a first-line antibiotic in the field of dentistry” (2006).

One must be aware of and consider some common complications that can arise in patients with severe odontogenic infections. As mentioned earlier, airway obstruction as seen with Ludwig’s angina can be one of the more serious complications. Ensuring that the patient has a patent airway is of upmost importance, achieving an open airway however, can be quite a challenge for the medical team. Candamourty et al. advise that a blind nasotracheal intubation can be quite dangerous in Ludwig’s angina patients because there is potential for significant bleeding and abscess rupture. Options to consider can include fiberoptic intubation via nasal route, or the “gold standard” elective tracheostomy under local anesthesia (2012).

Another common complication resulting from an odontogenic infection is trismus which occurs when the infection infiltrates the masticatory space resulting in inability to open the mouth to a normal range of 40 - 60 mm. This makes extractions or access to the site of infection more difficult, or even impossible. Trismus is yet another contributing factor which can make an odontogenic infection more difficult for the practitioner to effectively treat.

Both trismus and airway management issues are objective signs that a practitioner can look for when determining whether or not a patient requires admittance into an in-patient hospital setting. Other objective signs that should alert the physician include: fever over 101°F (38.3°C), dehydration requiring intravenous fluid therapy, need for incision and drainage, possible need for general anesthesia, patients with significant systemic health conditions, as well as immunocompromised patients (Flynn, 2000). Early recognition of these symptoms and proper diagnosing of pathology are two important tasks a physician can perform for their patient. Prevention of the initial spread of infection can spare the patient, physician, as well as the healthcare system the unwanted burdens of the aforementioned complications and treatments necessary for patients with severe odontogenic infections. Gams et al., demonstrated that the pathosis described in the above paragraphs “were associated with substantial morbidity and cost in a largely unsponsored patient population.” They went on to communicate to their peers that early treatment of odontogenic infections could spare unnecessary hospital admittances (2017).

The task of treating patients with severe odontogenic infections can be a daunting one; however, it is important to think logically when treatment planning, and to fully consider what has been demonstrated in this paper. Evidence-based treatment planning and problem solving that can be verified in literature will lead both the patient as well as the practitioner down a successful path. **AD**

References:

- Bahl, R., Sandhu, S., Singh, K., Sahai, N., & Gupta, M., (2014). Odontogenic infections: Microbiology and management. *Contemporary Clinical Dentistry*. 5(3): 307-311.
- Bali, R. K., Sharma, P., Gaba, S., Kaur, A., & Ghanghas, P., (2015). A review of complications of odontogenic infections. *National Journal of Maxillofacial Surgery*. 6(2): 136-143.
- Candamourty, R., Venkatachalam, S., Babu, M. R. R., & Kumar, G. S., (2012). Ludwig’s Angina—An emergency: A case report with literature review. *Journal of Natural Science, Biology, and Medicine*. 3(2): 206-208.
- Cho, A. W. (2015) Submandibular space infections (Ludwig’s Angina). In A. Bloom (Ed.), *UpToDate*. Retrieved June 9, 2017, from <https://www.uptodate.com/contents/submandibular-space-infections-ludwigs-angina/print>
- Dhandrajani, P.J., and Jonaidel, O., (2002). Trismus: Aetiology, Differential Diagnosis and Treatment. *Dental Update*. 29:88-94.
- Flynn, T. R., (2000). *The Swollen Face – Severe Odontogenic Infections*. *Emergency Medicine Clinics of North America*. 18(3):481-519.
- Flynn, T. R., Levi, M. H., and Kraut, R. A., (2006). *Severe Odontogenic Infections, Part 1: Prospective Report*. *Journal of Oral and Maxillofacial Surgery*. 64: 1093-1103.
- Flynn, T. R., Shanti, R. M., and Hayes, C., (2006). *Severe Odontogenic Infections, Part 1: Prospective Outcomes Study*. *Journal of Oral and Maxillofacial Surgery*. 64: 104-1113.
- Gams, K., Shewale, J., Demian, N., Khalil, K., and Banki, F., (2017). Characteristics, length of stay, and hospital bills associated with severe odontogenic infections in Houston, TX. *The Journal of the American Dental Association*. 148(4): 221-229.
- Jose, A., Nagori, S. A., Ongkila, B., and Roychoudhury, A., (2014). Odontogenic infection and pachymeningitis of the cavernous sinus. *British Journal of Oral and Maxillofacial Surgery*. 52: e27-e29.
- Lockhart, P. B., Durack, D. T., (1999). Oral microflora as a cause of endocarditis and other distant site infections. *Infectious Disease Clinics of North America*. 13(4): 833-850.
- Mougeot, F. K. B., Saunders, S. E., Brennan, M. T., and Lockhart, P. B., (2015). Associations between bacteremia from oral sources and distant-site infections: tooth brushing versus single tooth extractions. *Oral Surgery, Oral Medicine, Oral Pathology and Oral Radiology*. 119: 430-435.
- Obayashi, N., Arijii, Y., Goto, M., Izumi, M., Naitoh, M., Kurita, K., Shimozato, K., Arijii, E., (2004). Spread of odontogenic infection originating in the maxillary teeth: Computerized tomographic assessment. *Oral Surgery, Oral Medicine, Oral Pathology and Oral Radiology*. 98: 223-231.
- Sakamoto, H., Aoki, T., Kise, Y., Watanabe, D., and Sasaki, J., (2000). Descending necrotizing mediastinitis due to odontogenic infections. *Oral Surgery, Oral Medicine, Oral Pathology, and Oral Radiology*. 89: 412-419.
- Stefanopoulos, P. K., and Kolokotronis, A. E., (2004). The clinical significance of anaerobic bacteria in acute orofacial odontogenic infections. *Oral Surgery, Oral Medicine, Oral Pathology, and Oral Radiology*. 98: 398-408.
- Tomas, I., Alvarez, M., Limeres, J., and Diz, P., (2006). Clindamycin in dentistry: Is it an effective prophylaxis for endocarditis? *Oral Surgery, Oral Medicine, Oral Pathology, and Oral Radiology*. 1(6): 698-700.

now you know

INFORMATION FROM THE FDA

all you need to know about **hot topics**

Opioids • Dental Therapists • Student Debt • Board of Dentistry • Medicare/Medicaid

all in **one place**

floridadental.org/nyk



The latest news from the Florida Dental Association about major topics that affect dentistry in Florida. **A members-only benefit!**

For more reading, you can view our latest journal, *Today's FDA*; email blasts, *News Bites*; and, our blog, *Beyond the Bite*.



THE POWER OF THE COMPLETE TEAM

florida dental ASSOCIATION CONVENTION

THE OFFICIAL MEETING OF THE FDA



FREE PRE-REGISTRATION FOR FDA MEMBERS

PRE-REGISTRATION DEADLINE: 6/14

IT PAYS TO BE AN FDA MEMBER DENTIST!

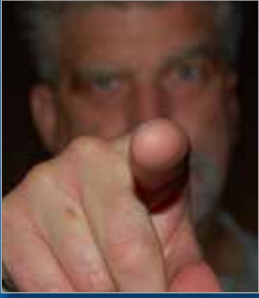INCLUDED IN YOUR FREE REGISTRATION:

- DISCOUNTED COURSE PRICING
- UP TO 18 HOURS OF FREE CE
- ACCESS TO THE EXHIBIT HALL
- NIGHTLY SOCIAL EVENTS
- FREE KEYNOTE SESSIONS
- DISCOUNTED REGISTRATION FEES FOR TEAM MEMBERS

Tip of the Tongue

A DENTAL JIGSAW PUZZLE

42 pieces | ages 8 and up



Hugh Wunderlich, DDS

I am puzzled. Maybe I need a dental consultant. My hygienist called this morning. She will be late because she is reconditioning the leather seats on her "beamer". Mrs. Robinson called. She claims the porcelain facing on her new anterior bridge exploded while she was flossing. Mr. Cobblepott called. He is still numb from an injection four days ago and his eye is droopy. The new software scheduling program will not boot-up due to a computer bug. It seems the staff likely picked up the "Ebola virus" from Africa while casino gambling online at lunch. Temporaries are temperamental. Metal frames are finicky. Nerves never numb.

I tried the morning huddle. You know the five minute meeting prior to the start of your day. Some consultants suggest this brief conference to identify potential problems. We would just identify that no one was a morning person and we were out of coffee. Some offices pray. They stand in a circle, holding hands, asking for strength to get through the day. Not a bad idea but I always thought the almighty had better things to do than to make my alginate set before my patient gags. One seminar suggests one patient per day. You pretty much made a temporary all day. It was \$4000 per unit but a great temporary. Another guru suggested the two minute crown prep and using Perio-Pak as the provisional material. The logic is that periodontists use it right after surgery – just thumb it on and lock it onto six adjacent teeth for two weeks. The prep is with diamonds as big as a Buick, cutting tooth, gum, bone, whatever is in the way. They will be begging for that off-color permanent crown. Like most, our office will huddle, pray and make temporaries somewhere between "all day" and Perio-Pak. These problems and solutions become like a jig-saw puzzle in life and a source of great dental stress. I choose to deal with them from the best consultant I know – my mother.

My mother taught me many things in life. Three of the best ones were - adding cream cheese to scrambled eggs, a complete sex lecture in only six words and how to handle problems the same way you approach a jig-saw puzzle. If you think about it you learned it too. As each problem or puzzle piece is dumped in front of you, they are identified and grouped together by color, size, shape, etc. The easiest pieces (as in the borders) are first. By addressing the easiest ones first many of the seemingly difficult tasks fall right into place. But here is the thing most people forget in applying the puzzle principle to life's problems – you look at the box. Each puzzle has a picture of the solution right on the box. It's the big picture. How does each task or piece fit into your personal goals? Step back and look at how it applies to the big picture. As each piece falls into place the puzzle gets easier to complete. All problems, dental or otherwise can be addressed this way once you apply them to the picture on your box. Find a friend or colleague to help you. The WCDDA can help with that. Chances are someone has solved that or a similar puzzle before. Oh and do not forget to have good lightning, a large card table, and to add cream cheese to your scrambled eggs.



WEST COAST DISTRICT DENTAL ASSOCIATION

A COMPONENT OF THE AMERICAN & FLORIDA DENTAL ASSOCIATIONS

1114 Kyle Wood Lane
Brandon, FL 33511
(813) 654-2500 Fax (813) 654-2505
lissette@wcdental.org
www.wcdental.org

PRESORTED
STANDARD
U.S. POSTAGE
PAID
TAMPA, FL
PERMIT NO 3239

Mission:
Helping Members Succeed

Values:
*Service, Commitment,
Integrity and Excellence*

Culture:
*The Reliable Resource
for Dentists.*

The WCDDA Newsletter is published two times a year, in the Fall and the Spring. The Editor of the association and staff organize, print and mail to membership. The position of the editor is elected by the Executive Cabinet and does not have a specified term. The editorial staff holds the right to deny ads submitted for publishing. The newsletter may publish signed articles relating to all phases of dentistry, but assumes no responsibility for opinions expressed by the contributors. Publication in this newsletter does not imply the West Coast District Dental Association endorses any products or services that are advertised. Views, editorials, news columns and/or articles are those of the author's and not necessarily of the editor, staff, or members of the West Coast District Dental Association.

EDITOR
Hugh Wunderlich, DDS, CDE

CO-EDITOR
Reza Iranmanesh, DMD

MANAGING EDITOR
Kelsey Bulnes, CMP

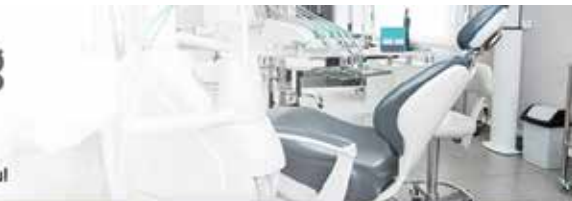EXECUTIVE DIRECTOR
Lissette Zuknick

THE WEST COAST DISTRICT
DENTAL ASSOCIATION
serves these counties:

- | | | |
|-----------|--------------|----------|
| Charlotte | Hardee | Manatee |
| Citrus | Hendry | Pasco |
| Collier | Hernando | Pinellas |
| DeSoto | Highlands | Polk |
| Glades | Hillsborough | Sarasota |
| | Lee | |

Thinking About Buying or Selling a **Dental Practice?**

With 28 years of experience and 12 state-wide local agents, Doctors Choice Can Help You!



J. Kenny Jones
Lic. Real Estate Broker
Pres. - Owner



Dr. Jack Saxonhouse
Palm Beach County



Morcie Smith, CFP
West Coast



Greg Jones
Broker Associate
Southeast Florida



Dr. Jerry Pyser
Statewide
Representation



Mary Ann Serkin
Northeast, FL



Ron Rubenstein
Practice Sales



Dr. Marshall Berger
Broward County



Michael Connor
Central Florida



Dr. Tony Hodge
Treasure Coast



Dr. Carlton Schwartz
Northwest, FL



Samantha Jones
Executive Secretary



Marc Oxenstein
Miami-Dade, FL



Melanie Aranda
Associate Placement

**Doctor's Choice
Lecture Series**

"Preparing to Sell Your Practice"

2019 Dates/Times TBA

Rated ★★★★★ by Previous Attendees!

DC Doctor's Choice

Call Us Today! **877.335.0380**

www.Doctors-Choice.com • Info@Doctors-Choice.com

Dental Practice Sales • Appraisals • Associate Placement • Commercial Real Estate